

Abdominal vascular trauma

Leslie M Kobayashi,¹ Todd W Costantini,¹ Michelle G Hamel,¹ Julie E Dierksheide,¹
Raul Coimbra²¹Division of Trauma, Surgical Critical Care, Burns and Acute Care Surgery, Department of Surgery, University of California San Diego, San Diego, California, USA²Department of Surgery, Division of Trauma, Surgical Critical Care, and Burns, University of California, San Diego, California, USA**Correspondence to**
Dr Raul Coimbra;
rcoimbra@ucsd.eduReceived 22 May 2016
Revised 25 June 2016
Accepted 30 June 2016**ABSTRACT**

Abdominal vascular trauma, primarily due to penetrating mechanisms, is uncommon. However, when it does occur, it can be quite lethal, with mortality ranging from 20% to 60%. Increased early mortality has been associated with shock, acidosis, hypothermia, coagulopathy, free intraperitoneal bleeding and advanced American Association for the Surgery of Trauma Organ Injury Scale grade. These patients often arrive at medical centers in extremis and require rapid surgical control of bleeding and aggressive resuscitation including massive transfusion protocols. The most important factor in survival is surgical control of hemorrhage and restoration of appropriate perfusion to the abdominal contents and lower extremities. These surgical approaches and the techniques of definitive vascular repair can be quite challenging, particularly to the inexperienced surgeon. This review hopes to describe the most common abdominal vascular injuries, their presentation, outcomes, and surgical techniques to control and repair such injuries.

INTRODUCTION

Abdominal vascular trauma is rare, lethal, and primarily associated with penetrating mechanisms. The most commonly injured abdominal vessels are the aorta, superior mesenteric artery (SMA), iliac arteries, inferior vena cava (IVC), portal vein (PV), and iliac veins. Mortality from abdominal vascular injuries in modern series remains high at 20–60%, with early deaths due to exsanguination and late deaths due to multisystem organ failure.¹

Presentation is dependent on whether the injury has resulted in tamponade (retroperitoneal hematoma) or free rupture into the peritoneal cavity. If the hematoma has ruptured, patients will likely present in volume unresponsive hemorrhagic shock; however, if the injury remains contained in the retroperitoneum, the patient may remain stable or be a transient responder to fluid resuscitation. When abdominal vascular injury is suspected, immediate large bore intravenous access, immediate surgical exploration, and appropriate resuscitation with 1:1:1 transfusion² following surgical control of bleeding are essential for any possibility of rescue. Active rewarming of fluids and other efforts to maintain normothermia such as elevated operating room temperature and Bair huggers are also important as hypothermia is likely given the volume of blood loss and body cavity exposure.

FREE INTRAPERITONEAL BLEEDING

Patients presenting with free intraperitoneal bleeding are typically unstable and swift measures must be taken to prevent rapid exsanguination and death. The patient should be widely prepped from

the chin to the knees and suction available before opening a tense hemoperitoneum. The abdomen is opened from the xyphoid to the pubis. Rapid packing of all four quadrants is then performed. An assistant uses a large hand-held retractor to lift the anterior abdominal wall while the surgeon inserts the left hand into the abdomen to protect the organs and uses the right hand to evacuate the clot and pack lap pads over the left hand. Packing of the liver and spleen should be performed both above and below the organs to create maximal tamponade. Once hemorrhage is controlled with packing, anesthesia should be allowed to resuscitate the patient, restoring circulating blood volume, at which point systematic exploration can be undertaken to identify injuries. If packing of all four quadrants fails to control blood loss, or if the patient arrests, supraceliac control of the aorta may be necessary. An assistant should retract the left lobe of the liver to the patient's right while the gastrohepatic ligament is opened vertically. The distal esophagus and stomach are then retracted. The aorta can then be manually compressed with a hand, sponge stick or aortic occluder. To clamp the aorta at the hiatus, the right crus of the diaphragm must be divided sharply and excess tissue cleared from either side of the aorta with blunt dissection. Posterior dissection of the aorta should be avoided to prevent injury to posterior arterial branches. A vascular clamp is then placed, completely occluding the aorta. Another option for clamping the aorta is via a left anterolateral thoracotomy. This is performed by making an incision from the sternum to the posterior axillary line just above the fifth rib. The intercostal muscles are divided sharply with scissors just above the fifth rib taking caution to avoid injury to the intercostal neurovascular bundle running inferior to the rib. The rib spreader is then placed with the handle lateral so that it will not impede extending the incision into a clamshell thoracotomy if necessary. The lung is then retracted anteriorly after division of the inferior pulmonary ligament. The pleura overlying the aorta is opened with scissors. Blunt dissection is utilized to clear the aorta anteriorly and posteriorly for ~1–2 cm, which allows for placement of the vascular clamp (a 'side bite' clamp preferentially) around the aorta. Care should be taken to avoid wide dissection of the thoracic aorta as this can result in avulsion of intercostal arteries and significant bleeding as well as iatrogenic esophageal injury. Palpation of a previously placed nasogastric tube may aid in rapid identification of the esophagus and avoidance of this devastating complication.^{3 4}

Another option for aortic control is resuscitative endovascular balloon occlusion of the aorta (REBOA). The REBOA catheter is placed into the

To cite: Kobayashi LM, Costantini TW, Hamel MG, et al. *Trauma Surg Acute Care Open* Published Online First: [please include Day Month Year] doi:10.1136/tsaco-2016-000015

aorta through the femoral artery via a direct cut down or percutaneously using the Seldinger technique. The balloon is positioned using fluoroscopy or X-ray, and aortic occlusion can be positioned depending on the location of suspected bleeding. There are three zones of inflation: zone 1 is from the left subclavian to the celiac, zone 2 is from the celiac to the renal arteries, and zone 3 is from the renal arteries to the iliac bifurcation. The larger 12 French (Fr) catheters typically used in the USA have required a femoral artery cut down for access; however, a 7 Fr catheter is now approved for use, allowing for percutaneous access, avoiding the need for a femoral artery cut down or suture repair of the arteriotomy, which may lead to increased use of this procedure.⁵

CONTAINED RETROPERITONEAL HEMATOMA

The retroperitoneum is divided into three zones. Zone I spans the midline of the abdomen and can be divided into the supramesocolic and inframesocolic regions; it contains the aorta, IVC, celiac, and superior and inferior mesenteric arteries (SMA/IMA). Zone 2 is located in the paracolic gutters bilaterally and contains the renal vessels and kidneys. Zone 3 begins at the sacral promontory and contains the iliac arteries and veins. The approach to contained retroperitoneal hematomas is dependent on the mechanism of injury, location, and suspected vascular injury. In general, suspected aortic and mesenteric arterial and left zone 2 injuries are approached via a left medial visceral rotation, while suspected IVC and right zone 2 injuries are approached via a right medial visceral rotation.⁴

During a left medial visceral rotation, the white line of Toldt is divided lateral to the entirety of the left colon and the left colon is rotated toward the patient's right upper quadrant. The spleen is mobilized by dividing the lienosplenic ligament. The stomach, left colon, spleen, and tail of the pancreas are then rotated medially off the retroperitoneum by placing a hand anterior to the kidney (modified left medial visceral rotation). Left-sided medial visceral rotation can also be performed posterior to the kidney, based on the surgeon's preference and location of injury. Rotation of the viscera will allow visualization of the aorta from its entry at the diaphragmatic hiatus to the bifurcation (figure 1).⁴

During the right medial visceral rotation, the white line of Toldt is divided lateral to the ascending colon from the base of the cecum and continued up to the hepatic flexure, and the mesentery of the right colon and small bowel is dissected off the

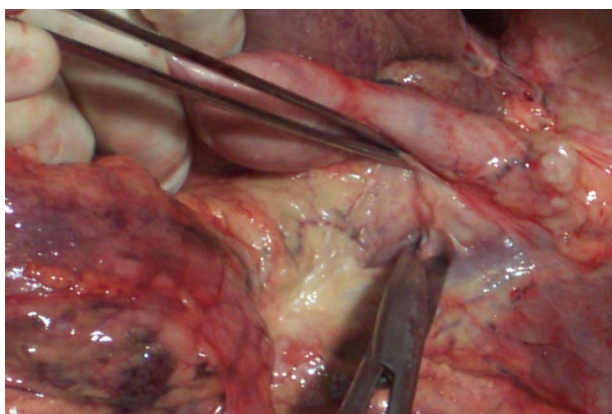


Figure 1 Exposure of the suprarenal aorta following left medial visceral rotation. Note the dense connective tissue that surrounds the suprarenal aorta, identified by displacing the gastro-oesophageal junction anteriorly.

retroperitoneum to its root. The duodenum is Kocherized by incising its lateral peritoneal attachments and is then mobilized until the head of the pancreas is exposed to the uncinate process and its posterior aspect visualized. The cecum and small bowel are swept out of the pelvis and toward the patient's left upper quadrant. A complete right medial visceral rotation exposes the IVC from the inferior border of the liver (suprarenal portion) to its bifurcation (figure 2).⁴

ZONE 1 Abdominal aorta

Injury to the abdominal aorta is associated with high morbidity and mortality rates ranging from 50% to 78% in several series.⁶⁻¹⁰ Injuries to the abdominal aorta are classified as diaphragmatic, suprarenal, and infrarenal, with diaphragmatic and suprarenal injuries carrying the highest mortality.

Diaphragmatic aortic injuries

Injuries to the diaphragmatic aorta present more often with contained hematoma than free rupture because of the dense connective tissue surrounding this portion of the aorta. Injuries to the diaphragmatic aorta can be exposed via laparotomy and entry into the lesser sac, left anterolateral thoracotomy, or via left medial visceral rotation with division of the left crus in the two o'clock position.¹¹ These approaches have been described previously in this chapter.

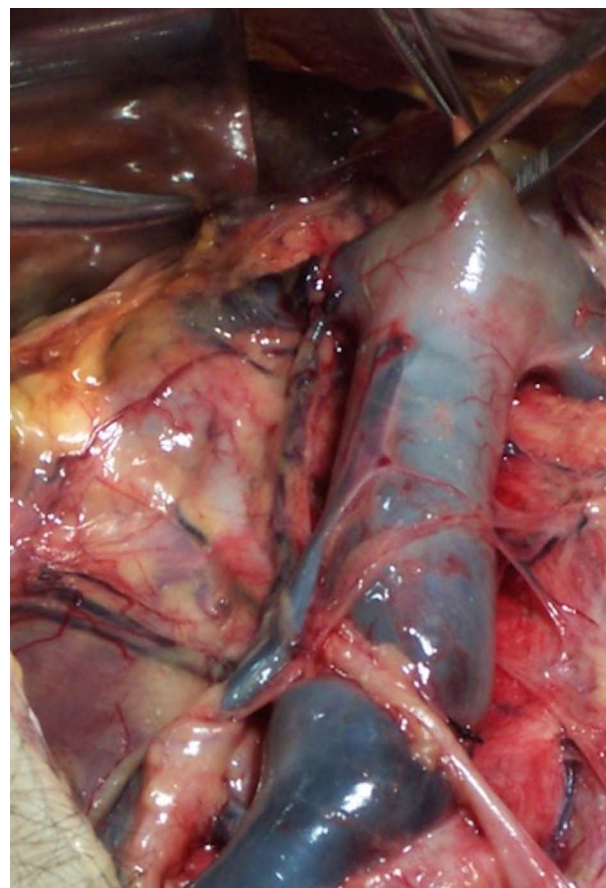


Figure 2 Exposure of the infrarenal, juxta-renal, and suprarenal IVC following right-sided medial visceral rotation. The exposure of the suprarenal IVC is obtained by displacing the inferior edge of the right lobe of the liver superiorly and after performing an extended Kocher maneuver.¹ IVC, inferior vena cava.

Suprarenal aortic injuries

Injuries to the suprarenal abdominal aorta are associated with worse outcomes compared to infrarenal aortic injuries.^{8,9} Initial efforts should be directed at gaining proximal control of the aorta to limit ongoing hemorrhage. The aorta may initially be controlled manually by applying pressure, with a hand or an aortic compression device at the hiatus of the diaphragm. Another option is to gain proximal control in the chest via a left anterolateral thoracotomy as previously described. Thoracotomy may also be necessary if the patient requires open cardiac massage. Once proximal control of the aorta has been achieved, exposure of the suprarenal aorta can begin. This is best accomplished by left-sided medial visceral rotation. Division of the left crus of the diaphragm may be required to fully expose the proximal abdominal aorta in order to gain vascular control and allow visualization of injuries proximal to the celiac artery. Distal control of the aorta with an aortic clamp must be achieved prior to repair of the injury. Once the injury is identified and isolated, care should be taken to examine both the anterior and posterior walls to evaluate for through-and-through injuries. Small injuries to the aorta should be repaired primarily with a 3-0 or 4-0 Prolene suture. If the defect in the aortic wall is sufficiently large that primary repair would result in significant narrowing of the aortic lumen, patch angioplasty can be performed using polytetrafluoroethylene (PTFE), Dacron, or an autologous vein. In some instances, significant tissue loss or destruction may require replacement with an interposition graft. A 12–18 mm PTFE or Dacron conduit should be chosen based on the size of the native aorta and anastomosed using a running 3-0 or 4-0 Prolene suture. If the patient is unstable, shunting of the aorta with a chest tube or other large bore Javid or Argyle shunt may be performed. Temporary intravascular shunts (TIVS) can be secured with silk ties, vessel loops, or umbilical tape; local flushing with heparinized saline can be used, but most evidence suggests systemic heparinization is unnecessary. While TIVS remain an attractive damage control option indications, type of shunt, dwell time, and long-term outcomes have yet to be clarified in the literature.

Infrarenal aortic injuries

Injuries to the infrarenal abdominal aorta should be accessed using an approach similar to that for abdominal aortic aneurysm repair. The small bowel is eviscerated to the patient's right and the transverse mesocolon is lifted cephalad. The retroperitoneum is then opened in the midline, beginning at the ligament of Treitz to expose the infrarenal aorta. Proximal control can be achieved by placing an aortic clamp just inferior to the left renal vein. For patients with loss of retroperitoneal tamponade and active bleeding, initial proximal control can be gained at the diaphragmatic hiatus as previously described. This can allow for a more controlled dissection of the infrarenal aorta, at which time the aortic clamp can be moved inferiorly to the infrarenal position. Injuries to the infrarenal aorta should be repaired as described above, using a 3-0 or 4-0 Prolene suture for small injuries, and a PTFE, Dacron, vein patch, or interposition graft for larger injuries.

Inferior vena cava

Similar to aortic injuries, IVC injuries carry a high morbidity and mortality (36–75%), and injuries are classified by location as infrarenal, suprarenal, or retrohepatic/suprahepatic.^{1,7,8,11–13}

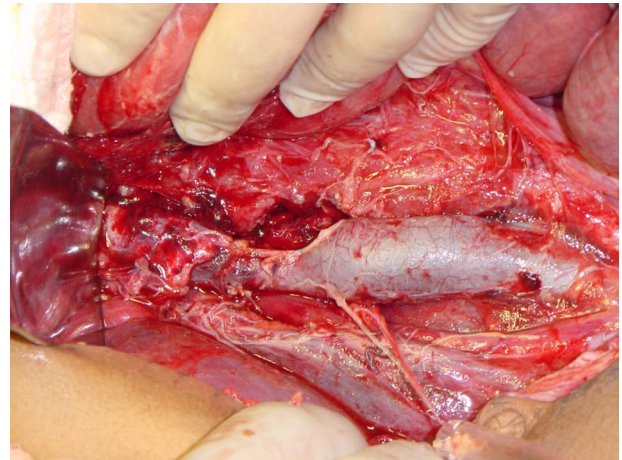


Figure 3 Lateral venorrhaphy of infrarenal IVC causing critical narrowing >40%. IVC, inferior vena cava.

Infrarenal IVC

The infrahepatic IVC is exposed via a right-sided medial visceral rotation. Infrarenal IVC injuries carry the lowest mortality rate.¹⁴ Injuries encompassing <50% of the vessel wall and those that can be closed transversely should be repaired with lateral venorrhaphy using a 4-0 or 5-0 Prolene suture (figure 3). Posterior defects should be searched for by rotating the vessel or enlarging the anterior defect.¹⁵ Defects larger than 50% of the circumference of the vessel, those where primary repair results in significant narrowing, and multiple adjacent injuries can be repaired with saphenous vein or prosthetic patch angioplasty (figure 4), as narrowing of >40% of the lumen should be avoided. In damage control situations, ligation of the infrarenal IVC can be considered (figure 5). Four-compartment lower extremity fasciotomies and bilateral lower extremity elevation should be performed immediately in order to decrease edema.

Suprarenal IVC

Infrahepatic, suprarenal injuries of the IVC are also exposed via right-sided medial visceral rotation. Of utmost importance to

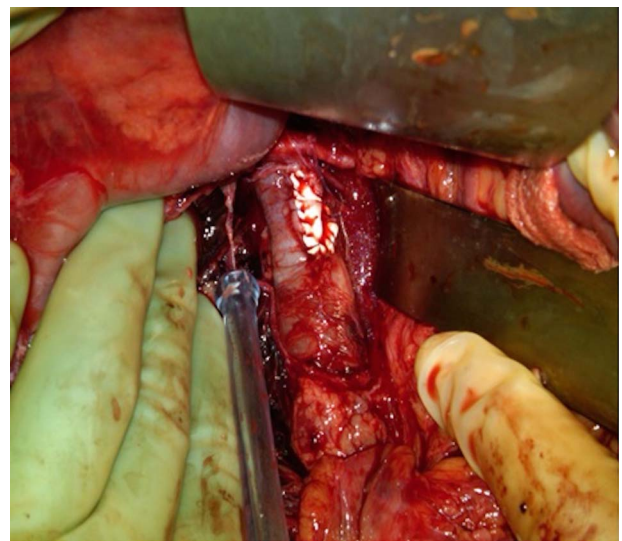


Figure 4 Prosthetic graft patch repair of IVC injury, preventing narrowing of the IVC lumen in a through-and-through gunshot wound. The posterior defect was repaired primarily after extending the anterior defect. IVC, inferior vena cava.

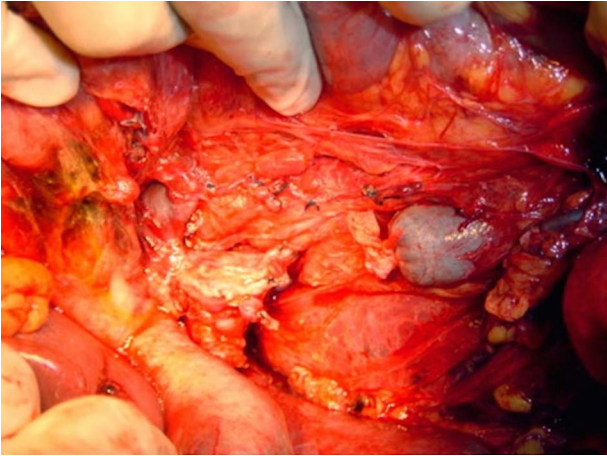


Figure 5 Ligated infrarenal IVC injury.¹ IVC, inferior vena cava.

expose the juxta-renal and supra-renal portions of the IVC is a complete Kocher maneuver, with mobilization of the duodenum until the posterior aspect of the head of the pancreas is completely visualized. Distal control above the renal veins is accomplished by retracting the inferior edge of the right lobe of the liver superiorly, thus creating a 2–3 cm space above the insertion of the renal veins in the IVC and allowing for dissection of each individual renal vein followed by the placement of vessel loops.

Retrohepatic/suprahepatic IVC

Surgical exposure and repair of retrohepatic and suprahepatic IVC injuries requires division of all hepatic ligaments and complete mobilization of the right lobe of the liver. In patients with associated liver injury, partial hepatectomy or enlargement of the existing liver laceration may be required for hemorrhage control as well as exposure of the retrohepatic IVC injury (figure 6). Atriocaval shunts have been described as an aid in repair of retrohepatic IVC injuries.¹⁶ A large chest tube is passed retrograde through the right atrium via thoracotomy or sternotomy incision into the IVC and advanced distal to the renal veins. The technique is performed with a Pringle maneuver.¹⁷ It must be kept in mind that mortality associated with the atriocaval shunt is extremely high, 70–90%, and if utilized it must be performed very early if there is to be any chance of survival.^{17 18} An alternative to atriocaval shunt placement is total hepatic isolation (Heaney maneuver). First, the suprahepatic IVC is clamped in

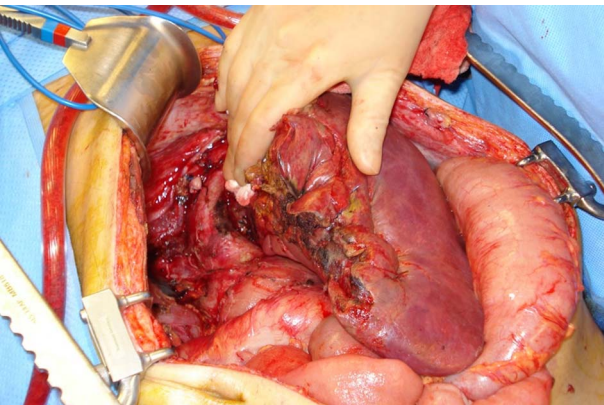


Figure 6 Retrohepatic IVC exposed by partial hepatectomy.¹ IVC, inferior vena cava.

the abdomen by mobilizing the liver and retracting it caudad. If the suprahepatic IVC is very short and cannot be clamped in the abdomen, the central tendon of the diaphragm can be divided to access the suprahepatic IVC or a median sternotomy can be performed, the pericardium opened, and the IVC clamped within the pericardium. Next, the infrahepatic IVC is clamped below the location of the injury and a Pringle maneuver is performed. Similar to atriocaval shunts, cardiac arrest is commonly associated with total hepatic isolation and outcomes are generally poor.^{6 11 19 20}

Celiac artery

The celiac artery can be exposed via left medial visceral rotation or through the lesser sac by dividing the gastrohepatic and left triangular ligaments.^{21–23} Proximal and distal control can be obtained with atraumatic vascular clamps or vessel loops. Small non-destructive injuries can be primarily repaired. In larger injuries or damage control situations, the celiac artery can be ligated due to extensive collateral circulation from the SMA.^{24 25} However, gallbladder ischemia has been noted; therefore, cholecystectomy is mandatory.^{23 25}

Superior mesenteric artery

The proximal SMA (table 1 Fullen zone I and II) can be exposed using a left medial visceral rotation²³ or directly through the root of the mesentery beneath the pancreas via the lesser sac with or without transection of the pancreas.²⁶ Distal SMA injuries (table 1 zone III) can be exposed from the left by dividing the ligament of Treitz, or from the right by mobilizing the duodenum off the SMA. Fullen zone IV injuries are often exposed by the existing injury in the distal mesentery and further delineation can be performed by opening the associated mesenteric hematoma or extending existing mesenteric lacerations.^{1 7 21 22 26}

Primary repair should be utilized whenever possible; in large or destructive injuries, vein patch angioplasty, interposition graft, and reimplantation can be considered but should only be considered in hemodynamically stable patients.

In unstable patients, primary repair should be performed if possible; if not, the injury can be ligated or shunted. Ligation of the SMA was noted to be well tolerated in two large series,²⁸ but bowel ischemia may occur, particularly when multiple injuries are present, and patients may benefit from temporary abdominal closure and a repeat exploration.^{1 7 13 28 29} TIVS are an alternative to ligation, but have rarely been reported in the literature, so outcomes and indications are still to be defined.^{30 31}

Table 1 SMA injuries, Fullen zone classification, and their associated bowel segments^{1 27}

Zone	Segment SMA	Ischemic risk	Bowel affected
I	Trunk proximal to 1st branch	Maximal	Jejunum, ileum, right colon
II	Trunk between inferior pancreaticoduodenal and middle colic	Moderate	Major segment, small bowel, right colon
III	Trunk distal to middle colic	Minimal	Minor segment or segments, small bowel or right colon
IV	Segmental branches (jejunal, ileal, colic)	None	None

SMA, superior mesenteric artery.

Owing to the difficult surgical approach to proximal mesenteric vascular injuries, endovascular repair is an attractive alternative/adjunct in the stable patient. There have been several case reports of patients with endovascular approaches to SMA injuries with successful hemorrhage control and no significant procedural complications.^{32–35}

Inferior mesenteric artery

Injuries to the IMA are rare and are generally approached directly and simple lacerations primarily repaired. In complex or destructive lesions, ligation is well tolerated because of the extensive collateral circulation.^{1 26} However, although extremely rare, IMA ligation may result in colorectal ischemia, particularly in patients with atherosclerotic disease and poor collateral blood flow.^{1 23}

SMV/portal vein

Injuries to the PV and superior mesenteric veins (SMV) are rare and generally due to penetrating trauma.^{36–40} Associated injuries are common; free intraperitoneal bleeding is common, resulting in advanced shock on presentation in the majority of patients, and associated mortality is high.¹

Operative approach to PV/SMV injuries should begin with application of a Pringle maneuver with placement of a large vascular clamp. The hematoma has often completed dissection of the portal structures and should be evacuated allowing visualization of the injury and formal proximal and distal control obtained with replacement of the atraumatic clamps or vessel loops around the injury. If extra length and access to more distal SMV injuries is required, a wide Kocher maneuver or a right medial visceral rotation can be performed and, if necessary, the neck of the pancreas can be divided.

PV injuries can be addressed by repair, reconstruction, or ligation. Ligation can be tolerated as long as the hepatic artery is patent. Ligation should be performed as early as possible in damage control situations, as early ligation has been associated with improved survival.^{1 41} Ligation of the PV may result in mesenteric venous congestion and reduced systemic venous return causing shock and possible arrest, a condition known as splanchnic hypervolemia/systemic hypovolemia.¹ SMV injuries can similarly be addressed by repair, reconstruction, or ligation. Ligation of the SMV is less likely than PV ligation to result in the syndrome of splanchnic hypervolemia/systemic hypovolemia.³⁶ Temporary abdominal closure and a second look procedure is prudent given the risks of intestinal ischemia and abdominal compartment syndrome.^{37 38} TIVS may be considered as a damage control option to ligation; however, data regarding patency rates and outcomes are lacking.

ZONE 2

All zone 2 retroperitoneal hematomas due to penetrating trauma should be explored; however, those due to blunt injury should be explored only if expanding or pulsatile. Primary sources of zone 2 hematomas include renal parenchymal injuries and injuries to the renal artery and vein.

Renal artery

Renal injuries are graded based on the AAST Renal OIS, which has been validated to predict outcome in patients with renal trauma.^{42 43} Exposure of zone 2 includes division of the lateral peritoneum and medial rotation of the viscera to expose Gerota's fascia. Gerota's is opened at the lateral aspect allowing elevation of the kidney and exposure of the renal hilum for manual compression or proximal control with vessel loops or

clamps. Some authors propose that proximal control of the renal hilum should be achieved prior to opening a perinephric hematoma.²³ However, experienced trauma surgeons argue that opening Gerota's fascia and quickly extruding the kidney then using the index and middle fingers to function as a renal hilar clamp is as effective and saves time. After the kidney is exposed and the renal vessels are compressed between the fingers of the surgeon, a vascular clamp can be applied and the injury assessed.

Arterial injuries can be primarily repaired or resected with graft placement. Small injuries may be repaired primarily with a 5-0 or 6-0 proline suture, while larger injuries will require mobilization and tension-free end-to-end repair. Complex arterial injury can require interposition graft with a saphenous vein or PTFE. Overall, the degree of renal vascular injury and physiological status of the patient will dictate if a nephrectomy is the best option. Verifying the presence of a contralateral kidney is mandatory prior to nephrectomy either with manual palpation, intravenous pyelogram, or preoperative imaging. Blunt injury can result in the formation of an intimal flap leading to thrombosis and occlusion of the renal artery often identified on a contrast CT scan. Endovascular stent placement can be utilized in stable patients; however, prompt identification of occlusion is required as delays to treatment increase the likelihood of nephrectomy.^{44 45}

ZONE 3

All retroperitoneal hematomas in zone 3 caused by penetrating trauma should be explored. As with zone 2 hematomas, zone 3 hematomas caused by blunt mechanisms should be explored only if the hematoma is pulsatile or expanding. Another indication for exploration of a pelvic hematoma is in the rare instance when a patient with blunt trauma presents with retroperitoneal hematoma and a femoral pulse is not identified. Blunt injury to the common and external iliac artery following blunt trauma with or without pelvic fractures is extremely rare, but it constitutes an absolute indication for exploration and restoration of flow to the affected limb. Pelvic angiography and angioembolization should be considered for hematomas or active extravasation of contrast in zone 3 from blunt injury when a pelvic fracture is present. Preperitoneal packing has also demonstrated efficacy in temporizing bleeding in blunt pelvic trauma as an adjunct or a bridge to angioembolization and pelvic fixation.^{46 47}

Iliac artery

Iliac vessel injuries have an incidence of 11% of all cardiovascular injuries with an overall mortality of 49%.^{48 49} Exposure of the iliac artery is achieved by eviscerating the small bowel to the patient's right side; the retroperitoneum can then be divided over the aortic bifurcation allowing visualization of the common iliac artery. Initial proximal control can be achieved by compressing the artery with a hand while the proximal artery is dissected free. Care should be taken to identify and preserve the ureter during dissection, which crosses over the iliac artery at the level of the bifurcation bilaterally. Vessel loops or vascular clamps can be used to gain definitive proximal control. Distal control of the external iliac artery can be obtained near the inguinal ligament. If the injury extends into the ipsilateral femoral artery, distal control of the femoral artery can be obtained below the inguinal ligament via a separate vertical thigh incision with or without division of the inguinal ligament. Control of the internal iliac artery is also necessary; this can be accomplished with the application of a vessel loop or atraumatic

clamp. Small injuries can be repaired primarily using a 4-0 or 5-0 Prolene suture. Larger injuries can be resected with end-to-end repair after adequate mobilization. PTFE or saphenous vein interposition grafts can also be considered for larger injuries in which adequate tension-free primary anastomosis cannot be performed after mobilization. Injuries to the iliac arteries may be associated with hollow viscus injuries. Interposition grafts placed through an infected field are at significant risk for later blowout, and gross contamination may require ligation of the arterial injury with subsequent extra-anatomic femoral-to-femoral or axillary-femoral bypass in a non-contaminated field to provide perfusion to the lower extremity.

Patients with severe injury and physiological derangement may require damage control procedures like TIVS (figure 7) to maintain blood flow to the lower extremity and prevent the development of lower extremity ischemia.⁵⁰⁻⁵² Distal pulses (palpated or Doppler tones) should be verified after securing the shunt. TIVS can be removed and replaced with a definitive vascular repair after the patient has been resuscitated and coagulopathy corrected.⁵² A study comparing patients requiring temporary shunting versus ligation for iliac artery injury found that the use of TIVS eliminated the need for later fasciotomies and amputations.⁵² Injuries to the internal iliac artery can be ligated with little consequence due to the rich pelvic collateral blood flow.⁵³

Advances in endovascular therapies have provided an alternative treatment for patients with injury to the iliac artery/vein. Placement of covered stent grafts across external and common iliac artery injuries have been described; however, these have been small series.⁵⁴⁻⁵⁵ Endovascular temporary balloon occlusion may be a temporizing measure to limit bleeding until exposure of the injured vessel can be obtained.⁵⁶ Angiographic embolization of the internal iliac artery or its branches with coils or gelfoam is common and is generally well tolerated.⁵⁷⁻⁵⁸

Iliac vein

Iliac vein injuries are frequently associated with iliac artery injuries.⁴⁸ Access to common iliac vein injuries, especially on the right side, may be limited by the overlying common iliac artery. Transection of the artery for visualization and repair of the venous injury has been described historically,⁵⁹ but is rarely advocated in modern times. Injuries to the common iliac vein and external iliac vein should be repaired primarily with a 4-0 or 5-0 Prolene suture. Larger venous injuries can be repaired using reverse saphenous

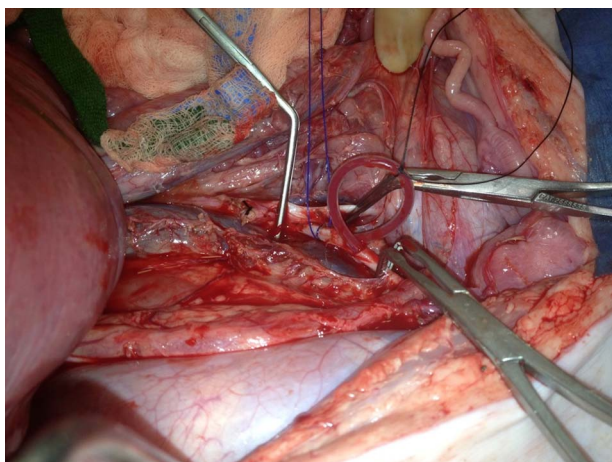


Figure 7 Looped temporary intravascular shunt within the iliac artery.

interposition grafts or vein patch repairs. A study of complex venous reconstructions after traumatic injury by Pappas *et al* demonstrated a patency rate of 73% at 30 days postrepair.⁶⁰ Postoperative anticoagulation should be considered if the venous repair results in significant narrowing of the diameter of the vein to prevent later thrombosis.²³ Ligation of the iliac veins can be considered for large injuries or patients who are unstable. Previous studies have shown that ligation of the common or external iliac vein is well tolerated with few adverse sequelae.⁶¹

ENDOVASCULAR APPROACHES FOR HEMORRHAGE CONTROL

There is great interest in endovascular approaches for control of hemorrhage and repair of vascular injury, including REBOA and endovascular stenting. REBOA can be utilized for proximal aortic occlusion in cases of exsanguination and hypotension. Small studies have demonstrated increased mean systolic blood pressure with the use of REBOA in uncontrolled hemorrhage secondary to pelvic fractures.⁵⁻⁵⁶⁻⁶² There has also been increasing utilization of endovascular stenting for vascular injuries, including thrombosis and dissection. This technique has been most utilized for aortic injuries, but there are case reports and small series of endovascular stenting for SMA, renal and iliac arterial injuries.⁴⁵⁻⁶³⁻⁶⁵ There is limited experience with the use of endovascular venous stenting, although this has been described in an IVC injury.⁶⁶

CONCLUSION

We hope this review can serve as an introduction and reminder of basic surgical techniques required for exposure, control, and repair of abdominal vascular injuries. Any surgeon faced with the injuries described in this review must balance optimal vascular repair with patient physiology and choose wisely when deciding on primary repair, complex reconstruction, and ligation. The majority of patients with abdominal vascular injuries will present in extremis; therefore, the surgeon must also be familiar with the principles of damage control resuscitation and damage control surgical approaches such as TIVS and temporary abdominal closure techniques. Knowledge of the principles described in this chapter is essential in managing these potentially catastrophic injuries.

Acknowledgements The authors acknowledge Dr Marcel Ruiz Albeiro Benavides for taking the photographs shown in figures 1 and 2.

Collaborators Dr Marcel Ruiz Albeiro Benavides.

Contributors LMK, TWC and RC contributed to the planning and writing of the manuscript. MGH and JED added additional information and revisions. MGH and LMK edited and formatted the revised manuscript.

Competing interests None declared.

Provenance and peer review Commissioned; externally peer reviewed.

Open Access This is an Open Access article distributed in accordance with the Creative Commons Attribution Non Commercial (CC BY-NC 4.0) license, which permits others to distribute, remix, adapt, build upon this work non-commercially, and license their derivative works on different terms, provided the original work is properly cited and the use is non-commercial. See: <http://creativecommons.org/licenses/by-nc/4.0/>

REFERENCES

- 1 Kobayashi L, Costantini T, Coimbra R. Mesenteric vascular trauma. In: Dua A, Desai S, Holcomb J, *et al*, eds. *Clinical review of vascular trauma*. Springer Medical Publishing, 2014:213–24.
- 2 Holcomb JB, Wade CE, Michalek JE, *et al*. Increased plasma and platelet to red blood cell ratios improves outcome in 466 massively transfused civilian trauma patients. *Ann Surg* 2008;248:447–58.

- 3 Feliciano DV, Moore EE, Biffl WL. Western trauma association critical decisions in trauma: management of abdominal vascular trauma. *J Trauma Acute Care Surg* 2015;79:1079–88.
- 4 Fildes J, Meredith JW, Hoyt DB, et al. Trauma ACoS. ASSET (Advanced Surgical Skills for Exposure in Trauma): exposure techniques when time matters: American College of Surgeons, 2010.
- 5 Stannard A, Eliason JL, Rasmussen TE. Resuscitative endovascular balloon occlusion of the aorta (REBOA) as an adjunct for hemorrhagic shock. *J Trauma* 2011;71:1869–72.
- 6 Coimbra R, Yang J, Hoyt DB. Injuries of the abdominal aorta and inferior vena cava in association with thoracolumbar fractures: a lethal combination. *J Trauma* 1996;41:533–5.
- 7 Asensio JA, Chahwan S, Hanpeter D, et al. Operative management and outcome of 302 abdominal vascular injuries. *Am J Surg* 2000;180:528–33; discussion 33–4.
- 8 Tyburski JG, Wilson RF, Dente C, et al. Factors affecting mortality rates in patients with abdominal vascular injuries. *J Trauma* 2001;50:1020–6.
- 9 Deree J, Shenvi E, Fortlage D, et al. Patient factors and operating room resuscitation predict mortality in traumatic abdominal aortic injury: a 20-year analysis. *J Vasc Surg* 2007;45:493–7.
- 10 Davis TP, Feliciano DV, Rozycki GS, et al. Results with abdominal vascular trauma in the modern era. *Am Surg* 2001;67:565–70; discussion 70–1.
- 11 Coimbra R, Hoyt D, Winchell R, et al. The ongoing challenge of retroperitoneal vascular injuries. *Am J Surg* 1996;172:541–4; discussion 5.
- 12 Eachempati SR, Robb T, Ivatury RR, et al. Factors associated with mortality in patients with penetrating abdominal vascular trauma. *J Surg Res* 2002;108:222–6.
- 13 Paul JS, Webb TP, Aprahamian C, et al. Intraabdominal vascular injury: are we getting any better? *J Trauma* 2010;69:1393–7.
- 14 Feliciano DV. Management of traumatic retroperitoneal hematoma. *Ann Surg* 1990;211:109–23.
- 15 Carr JA, Kralovich KA, Patton JH, et al. Primary venorrhaphy for traumatic inferior vena cava injuries. *Am Surg* 2001;67:207–13; discussion 13–14.
- 16 Schrock T, Blaisdell FW, Mathewson C Jr. Management of blunt trauma to the liver and hepatic veins. *Arch Surg* 1968;96:698–704.
- 17 Burch JM, Feliciano DV, Mattox KL. The atriocaval shunt. Facts and fiction. *Ann Surg* 1988;207:555–68.
- 18 David Richardson J, Franklin GA, Lukan JK, et al. Evolution in the management of hepatic trauma: a 25-year perspective. *Ann Surg* 2000;232:324–30.
- 19 Coimbra R, Prado PA, Araujo LH, et al. Factors related to mortality in inferior vena cava injuries. A 5 year experience. *Int Surg* 1994;79:138–41.
- 20 Hansen CJ, Bernadas C, West MA, et al. Abdominal vena caval injuries: outcomes remain dismal. *Surgery* 2000;128:572–8.
- 21 Asensio JA, Forno W, Roldan G, et al. Visceral vascular injuries. *Surg Clin North Am* 2002;82:1–20.
- 22 Asensio JA, Soto SN, Forno W, et al. Abdominal vascular injuries: the trauma surgeon's challenge. *Surg Today* 2001;31:949–57.
- 23 Dente C, Feliciano DV. Abdominal vascular injury. In: Feliciano DV, Mattox KL, Moore EE, eds. *Trauma*. New York, NY: McGraw Hill, 2008:737–57.
- 24 Graham JM, Mattox KL, Beall AC Jr, et al. Injuries to the visceral arteries. *Surgery* 1978;84:835–9.
- 25 Asensio JA, Petrone P, Kimbrell B, et al. Lessons learnt in the management of thirteen celiac axis injuries. *South Med J* 2005;98:462–6.
- 26 Hoyt DB, Coimbra R, Potenza BM, et al. Anatomic exposures for vascular injuries. *Surg Clin North Am* 2001;81:1299–330.
- 27 Fullen WD, Hunt J, Altemeier WA. The clinical spectrum of penetrating injury to the superior mesenteric arterial circulation. *J Trauma* 1972;12:656–64.
- 28 Asensio JA, Britt LD, Borzotta A, et al. Multiinstitutional experience with the management of superior mesenteric artery injuries. *J Am Coll Surg* 2001;193:354–65.
- 29 Asensio JA, Berne JD, Chahwan S, et al. Traumatic injury to the superior mesenteric artery. *Am J Surg* 1999;178:235–9.
- 30 Reilly PM, Rotondo MF, Carpenter JP, et al. Temporary vascular continuity during damage control: intraluminal shunting for proximal superior mesenteric artery injury. *J Trauma* 1995;39:757–60.
- 31 Subramanian A, Vercruyse G, Dente C, et al. A decade's experience with temporary intravascular shunts at a civilian level I trauma center. *J Trauma* 2008;65:316–24; discussion 24–6.
- 32 Hagiwara A, Takasu A. Transcatheter arterial embolization is effective for mesenteric arterial hemorrhage in trauma. *Emerg Radiol* 2009;16:403–6.
- 33 Demirel S, Winter C, Rappich B, et al. Stab injury of the superior mesenteric artery with life threatening bleeding—endovascular treatment with an unusual technique. *VASA* 2010;39:268–70.
- 34 Kakizawa H, Toyota N, Hieda M, et al. Traumatic mesenteric bleeding managed solely with transcatheter embolization. *Radiat Med* 2007;25:295–8.
- 35 Asayama Y, Matsumoto S, Isoda T, et al. A case of traumatic mesenteric bleeding controlled by only transcatheter arterial embolization. *Cardiovasc Intervent Radiol* 2005;28:256–8.
- 36 Coimbra R, Filho AR, Nesser RA, et al. Outcome from traumatic injury of the portal and superior mesenteric veins. *Vasc Endovascular Surg* 2004;38:249–55.
- 37 Fraga GP, Bansal V, Fortlage D, et al. A 20-year experience with portal and superior mesenteric venous injuries: has anything changed? *Eur J Vasc Endovasc Surg* 2009;37:87–91.
- 38 Pearl J, Chao A, Kennedy S, et al. Traumatic injuries to the portal vein: case study. *J Trauma* 2004;56:779–82.
- 39 Asensio JA, Petrone P, Garcia-Nunez L, et al. Superior mesenteric venous injuries: to ligate or to repair remains the question. *J Trauma* 2007;62:668–75; discussion 675.
- 40 Jurkovich GJ, Hoyt DB, Moore FA, et al. Portal triad injuries. *J Trauma* 1995;39:426–34.
- 41 Stone HH, Fabian TC, Turkleson ML. Wounds of the portal venous system. *World J Surg* 1982;6:335–41.
- 42 Shariat SF, Roehrborn CG, Karakiewicz PI, et al. Evidence-based validation of the predictive value of the American Association for the Surgery of Trauma kidney injury scale. *J Trauma* 2007;62:933–9.
- 43 Moore EE, Shackford SR, Pachter HL, et al. Organ injury scaling: spleen, liver, and kidney. *J Trauma* 1989;29:1664–6.
- 44 Carroll PR, McAninch JW, Klosterman P, et al. Renovascular trauma: risk assessment, surgical management, and outcome. *J Trauma* 1990;30:547–52; discussion 553–4.
- 45 Lee JT, White RA. Endovascular management of blunt traumatic renal artery dissection. *J Endovasc Ther* 2002;9:354–8.
- 46 Cothren CC, Osborn PM, Moore EE, et al. Preperitoneal pelvic packing for hemodynamically unstable pelvic fractures: a paradigm shift. *J Trauma* 2007;62:834–9.
- 47 Cullinane DC, Schiller HJ, Zielinski MD, et al. Eastern Association for the Surgery of Trauma practice management guidelines for hemorrhage in pelvic fracture—update and systematic review. *J Trauma* 2011;71:1850–68.
- 48 Asensio JA, Petrone P, Roldan G, et al. Analysis of 185 iliac vessel injuries: risk factors and predictors of outcome. *Arch Surg* 2003;138:1187–93; discussion 1193–4.
- 49 Mattox KL, Feliciano DV, Burch J, et al. Five thousand seven hundred sixty cardiovascular injuries in 4459 patients. Epidemiologic evolution 1958 to 1987. *Ann Surg* 1989;209:698–705; discussion 706–7.
- 50 Rasmussen TE, Clouse WD, Jenkins DH, et al. The use of temporary vascular shunts as a damage control adjunct in the management of wartime vascular injury. *J Trauma* 2006;61:8–12; discussion 12–15.
- 51 Rasmussen TE, Dubose JJ, Asensio JA, et al. Military Liaison Committee of the American Association for the Surgery of Trauma. Tourniquets, vascular shunts, and endovascular technologies: esoteric or essential? A report from the 2011 AAST Military Liaison Panel. *J Trauma Acute Care Surg* 2012;73:282–5.
- 52 Ball CG, Feliciano DV. Damage control techniques for common and external iliac artery injuries: have temporary intravascular shunts replaced the need for ligation? *J Trauma* 2010;68:1117–20.
- 53 DuBose J, Inaba K, Barmparas G, et al. Bilateral internal iliac artery ligation as a damage control approach in massive retroperitoneal bleeding after pelvic fracture. *J Trauma* 2010;69:1507–14.
- 54 Boufi M, Bordon S, Dona B, et al. Unstable patients with retroperitoneal vascular trauma: an endovascular approach. *Ann Vasc Surg* 2011;25:352–8.
- 55 Starnes BV, Arthurs ZM. Endovascular management of vascular trauma. *Perspect Vasc Surg Endovasc Ther* 2006;18:114–29.
- 56 Martinelli T, Thony F, Declety P, et al. Intra-aortic balloon occlusion to salvage patients with life-threatening hemorrhagic shocks from pelvic fractures. *J Trauma* 2010;68:942–8.
- 57 Velmahos GC, Demetriades D, Chahwan S, et al. Angiographic embolization for arrest of bleeding after penetrating trauma to the abdomen. *Am J Surg* 1999;178:367–73.
- 58 Costantini TW, Bosarge PL, Fortlage D, et al. Arterial embolization for pelvic fractures after blunt trauma: are we all talk? *Am J Surg* 2010;200:752–7; discussion 7–8.
- 59 Chapellier X, Sockeel P, Baranger B. Management of penetrating abdominal vessel injuries. *J Vasc Surg* 2010;147:e1–12.
- 60 Pappas PJ, Haser PB, Teehan EP, et al. Outcome of complex venous reconstructions in patients with trauma. *J Vasc Surg* 1997;25:398–404.
- 61 Timberlake GA, Kerstein MD. Venous injury: to repair or ligate, the dilemma revisited. *Am Surg* 1995;61:139–45.
- 62 Morrison JJ, Percival TJ, Markov NP, et al. Aortic balloon occlusion is effective in controlling pelvic hemorrhage. *J Surg Res* 2012;177:341–7.
- 63 Whigham CJ Jr, Bodenhamer JR, Miller JK. Use of the Palmaz stent in primary treatment of renal artery intimal injury secondary to blunt trauma. *J Vasc Interv Radiol* 1995;6:175–8.
- 64 Villas PA, Cohen G, Putnam SG III, et al. Wallstent placement in a renal artery after blunt abdominal trauma. *J Trauma* 1999;46:1137–9.
- 65 Lyden SP, Srivastava SD, Waldman DL, et al. Common iliac artery dissection after blunt trauma: case report of endovascular repair and literature review. *J Trauma* 2001;50:339–42.
- 66 Castelli P, Caronno R, Piffaretti G, et al. Emergency endovascular repair for traumatic injury of the inferior vena cava. *Eur J Cardiothorac Surg* 2005;28:906–8.