

Impact of circle of Willis anatomy in traumatic blunt cerebrovascular injury-related stroke

Charles P Shahan,¹ Richard I Gray,² Martin A Croce,¹ Timothy C Fabian¹¹Department of Surgery,
University of Tennessee Health
Science Center, Memphis,
Tennessee, USA²Department of Radiology,
University of Tennessee Health
Science Center, Memphis,
Tennessee, USA

Correspondence to

Dr Timothy C Fabian;
tfabian@uthsc.eduPresented at the American
College of Surgeons Clinical
Congress, Washington, DC,
October 2016

Received 18 February 2017

Revised 17 March 2017

Accepted 24 March 2017

ABSTRACT

Background Cerebral vascular anatomy, specifically the circle of Willis (COW), plays an unstudied role in the development of stroke after blunt cerebrovascular injury (BCVI; carotid and vertebral). Variant anatomy is very common, and certain variants such as persistent fetal circulation (enlarged posterior communicating artery) may improve collateralization between the anterior (carotid) and posterior (vertebral) circulations. Identifying patients at increased stroke risk may allow tailored anticoagulation, the mainstay of therapy. This study constitutes the first attempt to identify vascular anatomy patterns associated with stroke, with the hypothesis that normal anatomy would protect against stroke.

Study design Radiographic images from patients with BCVI-related stroke from 2005 to 2014 were identified. Patients with stroke were compared with injury-matched, non-stroke controls. Normal COW anatomy is defined as the presence of all vessels without hypoplasia.

Results Of 457 patients BCVI, 22 (4.8%) BCVI-related patients with stroke and matched controls were reviewed. 9 (41%) patients with stroke and 2 (9%) controls had normal COW anatomy (OR=7.1, 95% CI 1.28 to 33.3). Persistent fetal-type circulation was found in 6 controls and 1 patient with stroke, resulting in a 7.9-fold decreased risk of stroke with this variant (OR=0.13, 95% CI 0.003 to 1.26).

Conclusions Cerebral vascular anatomy has a role in BCVI-related stroke. Normal anatomy is not protective; however, the increased collateral flow provided by a persistent fetal-type enlarged posterior communicating artery is likely protective. The identification of high-risk patients may eventually allow for more tailored treatment. Prospective, multi-institutional trials are needed to further reduce the incidence BCVI-related stroke.

Level of evidence Prognostic and epidemiological, level III.

BACKGROUND

First described in 1872 by Verneuil,¹ and thought to be exceedingly rare until the 1980s, blunt cerebrovascular injury (BCVI) is still recognized as a relatively uncommon but potentially devastating entity. Improved imaging and increased screening along with the regionalization of trauma care over the past 30 years has led to an incidence of ~2% of all patients suffering blunt trauma.^{2–5} Without treatment, these injuries can result in a stroke 10–40% of the time, with the rate being variable by the injury grade and the vessel(s) injured.^{2–6–8}

Cerebral vascular anatomy is typically described as being divided into anterior and posterior circulations, with the vessels that make up the circle of Willis (COW) providing communication between the two halves (figure 1). Variants in COW anatomy are very common, with only 20% of patients in anatomical studies having a complete circle without any hypoplastic segments.⁹ Variations in cerebral vascular anatomy, and specifically the COW, have been implicated in increased risk of ischemia due to the potential loss of collateral flow.^{10–12}

Logically the incidence of stroke resulting from BCVI that limits cerebral blood flow should be influenced by cerebral vascular anatomy and collateral flow; however, this has not previously been studied. It has been hypothesized that having a normal, intact COW should be protective against ischemia, and that the converse should be true with any variant that limits collateralization; however, this has never been tested scientifically. Further knowledge of these risks could have profound treatment implications, especially in identifying those patients at increased risk of stroke and, therefore, those in whom more aggressive therapy may be warranted.

The purpose of this study was to evaluate the anatomy of those patients with BCVI-related stroke, and to determine if any anatomical variants do in fact alter the risk of stroke. Our hypothesis, based on the previously published stroke literature, was that a normal COW would be protective against BCVI-related stroke.

METHODS

Patients treated for BCVI at our institution from 2005 to 2015 were reviewed for inclusion in the study. Data including demographics, injuries, therapies, imaging, and development of stroke were collected. Patients were excluded if imaging was not available for review, or an acceptable matching control patient could not be identified. Ethical approval was obtained from the University of Tennessee Health Science Center Institutional Review Board.

A neuroradiologist reviewed all available imaging including CT, CT angiography, digital subtraction angiography (DSA), MRI, and MR angiography. All patients with stroke were first confirmed to have a stroke pattern that could be attributed to BCVI. Control patients were first matched by BCVI, then by age, gender, and race when possible. Cerebral vascular anatomy was reviewed in detail to describe all COW vessels, any hypoplasia, and any other variation from the classically described complete COW, including but not limited to any persistent

To cite: Shahan CP, Gray RI, Croce MA, et al. *Trauma Surg Acute Care Open* Published Online First: [please include Day Month Year] doi:10.1136/tsaco-2017-000086

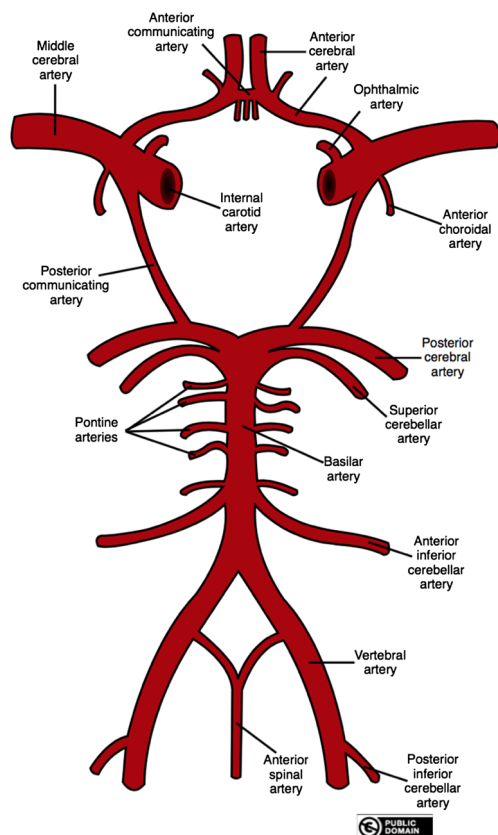


Figure 1 Circle of Willis (COW).

fetal anatomy or agenesis. COW anatomy was considered normal when all vessels were present without any evidence of hypoplasia or other collateralization.

Data were managed using REDCap electronic data capture tools hosted at the University of Tennessee Health Science Center.¹³ Statistical analysis was carried out in SAS V9.4 (SAS Institute, Cary, North Carolina, USA). Demographics were compared using a two-sample t-test or Wilcoxon rank-sum test, while risk of stroke was determined by exact conditional logistic regression analysis for the matched pairs. *p* Values <0.05 and ORs that did not include 1 were considered statistically significant.

RESULTS

Over the study period 457 patients were diagnosed with BCVI, and 37 (8%) patients were identified as having a BCVI-related stroke. Of these, 11 patients did not have a suitable injury-matched control for inclusion in analysis, while 4 did not have adequate imaging available for review and were not included in analysis. The characteristics of the 22 patients and their matched controls are shown in table 1. The only significant difference between the two groups was injury severity score, as would be expected in the patients suffering a stroke. The percentage of patients treated with heparin and antiplatelet therapy was not significantly different between the two groups.

Normal COW anatomy was described in 9 (41%) of the patients with stroke and 2 (9%) of the control patients. This made patients with a normal COW 5.8 times more likely to experience a stroke (OR=5.78, 95% CI 1.15 to 28.6, *p*=0.0339). The most common COW variant seen was a fetal-type enlarged persistent posterior communicating artery

Table 1 Patient characteristics

	Stroke (n=22)	Control (n=22)	<i>p</i> Value
Male (%)	45	59	0.5467
Age*	36±15	40±17	0.5261
Motor vehicle accident (%)	86	82	0.7379
Injury severity score†	38 (34–50)	29 (22–36)	0.0050
Treated with heparin (%)	74	94	0.1797

*Mean±SD.

†Median (IQR).

(PCOM). This fetal-type PCOM was seen in 6 (27%) of the control patients and only in 1 (5%) patient with stroke. The presence of a fetal-type PCOM was associated with a 7.6-fold decrease in the risk of stroke, a finding which did not achieve statistical significance (OR=0.13, 95% CI 0.003 to 1.26, *p*=0.0946).

The anterior communicating artery was absent in four of the control patients and three patients with (OR=1.5, 95% CI 0.172 to 17.959, *p*=1.00). In three patients with both the right and the left posterior communicating arteries were missing, resulting in completely separated anterior and posterior circulations, an occurrence which was not seen in any of the control patients (OR=9.0, 95% CI 0.6596 to 122.7942, *p*=0.0833). Eleven (50%) of the patients had a stroke that appeared to be limited to a single cerebral vessel distribution, while the remaining half suffered strokes in a multivessel distribution.

DISCUSSION

This study was designed to determine if there are variants of COW anatomy that effect the risk of stroke in patients with BCVI. Our hypothesis was incorrect; having a normal COW does not seem to be enough to provide protection against BCVI-related stroke. We believe this to be the most important finding of this study as it is contrary to what we have long believed to be true regarding cerebral vascular anatomy in BCVI. Interestingly, this is contrary to most of what has been published regarding other causes of stroke.^{14–16} Our best explanation for this discrepancy is that the pathophysiology of the stroke development with BCVI is often different from other causes of stroke. Acute proximal flow limitation of the internal carotid artery (ICA) should not commonly be seen outside of trauma, making this a somewhat unique cause of stroke.

Difficulty arises in describing the large number of COW anatomical variants, and there are some inconsistencies in the literature. There is specifically a lack of uniformity in anatomical patterns described as ‘fetal’. The most common usage appears to describe a posterior cerebral artery that arises entirely from the ICA, making cerebral perfusion even more dependent on the anterior circulation.¹⁷ Our description of a fetal-type PCOM refers to the setting of a PCOM that has a larger diameter than the first segment of the posterior cerebral artery.

Our finding suggesting that an enlarged PCOM may be protective is supported by the literature. Hendrikse *et al*¹⁸ showed that enhanced collateralization from the PCOM limited the development of border zone infarcts in patients with unilateral ICA stenosis. This would make sense since the PCOM serves to collateralize flow between the anterior and posterior circulations, and having a larger conduit should improve collateralization. We believe that the small number of patients in our study limited this finding from reaching statistical significance, but should not be discounted and deserves further evaluation.

Another important finding that did not achieve statistical significance was the bilateral absence of a PCOM resulting in isolated anterior and posterior circulations. Three of the patients suffering a stroke were noted to have this condition, while all of the control patients had at least one hypoplastic PCOM. Isolated anterior and posterior circulations would seem to place a patient with flow-limiting BCVI at higher risk of stroke, and thus we believe that these patients deserve heightened observation and potentially may need more aggressive intervention.

Antithrombotic therapy continues to be the standard therapy for BCVI, and has led to substantial reductions in the rate of stroke since the 1980s.^{19–20} While our data are not strong enough to support changes to a treatment algorithm, there may be very select patients who benefit from early stent placement in flow-limiting injuries, and cerebral vascular anatomy should probably factor into such a decision. The body of literature supporting endovascular interventions for acute stroke outside of trauma has grown, showing promising results for interventions from thrombectomy to stent placement.^{21–22} While routine stent placement has been shown to provide no real benefit to patients with BCVI, it may be worthwhile to evaluate the potential role of endovascular interventions in those who develop ischemia in an effort to reduce morbidity and improve outcomes, while keeping in mind that the results of the medical stroke literature may not be generalizable to this specific cause of stroke.

An important point of discussion which unfortunately lacks data is the exact nature of BCVI-related stroke: low flow and embolic. It has been hypothesized that flow-limiting lesions are likely to cause low-flow ischemia and thus more likely to affect the distribution of multiple cerebral arteries. In contrast, pseudoaneurysms are thought to be a more likely source of embolic stroke resulting in single-vessel distribution ischemia. In this study, the strokes were evenly divided between single-vessel and multi-vessel distribution, which is the best surrogate that we have for determining the etiology of stroke in this setting. This aspect of BCVI-related stroke may be critical to the advancement of treatment. For example, flow-limiting lesions that may result in a stroke would seem less likely to be effectively treated with antithrombotic therapy alone. There are many barriers to advancing our understanding of this aspect of BCVI-related stroke: definitive diagnosis of embolic versus low-flow strokes, confounding anatomy, and pre-existing vascular disease to start. Unfortunately, there is a paucity of data investigating the etiology of stroke following BCVI but we believe this may be one of the most important directions of future study if the incidence of stroke and outcomes are to be further improved.

The most important limitation of this study is the small cohort of patients able to be included. The effectiveness of anticoagulation in preventing BCVI-related stroke has fortunately made it difficult to accrue a sizable number of patients for analysis. Selection bias may also exist with regard to the anatomical variants observed, again due to the small number of patients available. Additionally, bias may exist in the interpretation of the imaging, as it was not possible to provide complete imaging for detailed analysis and blind the radiologist to the stroke status of each patient. Generalizability may be limited as our institution is one of very few that continues to perform confirmatory DSA to confirm the diagnosis of BCVI at admission to limit false-positive diagnoses.

CONCLUSION

COW anatomy is important to the generation of BCVI-related stroke. Contrary to our long-held hypothesis, the presence of

normal cerebral vascular anatomy is not enough to protect against stroke. Completely separate anterior and posterior cerebral circulation likely places patients at higher risk of stroke, while the presence of a fetal-type PCOM may be protective, but these findings deserve further study. Owing to the relatively low incidence of BCVI, cooperative multi-institutional trials will be required to continue advancement in the prevention of BCVI-related stroke.

Contributors CPS, RIG and TCF were involved in study concept and design. CPS and RIG were involved in acquisition of data. CPS, TCF and MAC were involved in analysis and interpretation. CPS and TCF were involved in drafting of the manuscript. TCF and MAC were involved in critical revision.

Competing interests None declared.

Ethics approval University of Tennessee Health Science Center Institutional Review Board.

Provenance and peer review Not commissioned; externally peer reviewed.

Open Access This is an Open Access article distributed in accordance with the Creative Commons Attribution Non Commercial (CC BY-NC 4.0) license, which permits others to distribute, remix, adapt, build upon this work non-commercially, and license their derivative works on different terms, provided the original work is properly cited and the use is non-commercial. See: <http://creativecommons.org/licenses/by-nc/4.0/>

REFERENCES

- Verneuil M. Contusions multiples deiré violent hémiplegie droite signes de compression cérébrale. *Bull Acad Natl Med* 1872;1:46–56.
- Biffi WL, Ray CE, Moore EE, Franciose RJ, Aly S, Heyrosa MG, Johnson JL, Burch JM. Treatment-related outcomes from blunt cerebrovascular injuries: importance of routine follow-up arteriography. *Ann Surg* 2002;235:699–706. discussion 706–7.
- Fabian TC, Patton Jh Jr, Croce MA, Minard G, Kudsk KA, Pritchard FE. Blunt carotid injury. Importance of early diagnosis and anticoagulant therapy. *Ann Surg* 1996;223:513–22; discussion 22–5.
- Miller PR, Fabian TC, Bee TK, Timmons S, Chamsuddin A, Finkle R, Croce MA. Blunt cerebrovascular injuries: diagnosis and treatment. *J Trauma* 2001;51:279–85. discussion 85–6.
- Paulus EM, Fabian TC, Savage SA, Zarza BL, Botta V, Dutton W, Croce MA. Blunt cerebrovascular injury screening with 64-channel multidetector computed tomography: more slices finally cut it. *J Trauma Acute Care Surg* 2014;76:279–83. discussion 84–5.
- Cothren CC, Biffi WL, Moore EE, Kashuk JL, Johnson JL. Treatment for blunt cerebrovascular injuries: equivalence of anticoagulation and antiplatelet agents. *Arch Surg* 2009;144:685–90.
- Emmett KP, Fabian TC, Dicocco JM, Zarza BL, Croce MA. Improving the screening criteria for blunt cerebrovascular injury: the appropriate role for computed tomography angiography. *J Trauma* 2011;70:1058–63. discussion 63–5.
- Stein DM, Boswell S, Sliker CW, Lui FY, Scalea TM. Blunt cerebrovascular injuries: does treatment always matter? *J Trauma* 2009;66:132–43; discussion 43–4.
- Riggs HE, Rupp C. Variation in form of circle of Willis. The relation of the variations to collateral circulation: anatomic analysis. *Arch Neurol* 1963;8:8–14.
- Lee JH, Choi CG, Kim DK, Kim GE, Lee HK, Suh DC. Relationship between circle of Willis morphology on 3D time-of-flight MR angiograms and transient ischemia during vascular clamping of the internal carotid artery during carotid endarterectomy. *AJNR Am J Neuroradiol* 2004;25:558–64.
- Feezor RJ, Martin TD, Hess PJ, Klodell CT, Beaver TM, Huber TS, Seeger JM, Lee WA. Risk factors for perioperative stroke during thoracic endovascular aortic repairs (TEVAR). *J Endovasc Ther* 2007;14:568–73.
- Jongen JC, Franke CL, Ramos LM, Wilmink JT, Van Gijn J. Direction of flow in posterior communicating artery on magnetic resonance angiography in patients with occipital lobe infarcts. *Stroke* 2004;35:104–8.
- Harris PA, Taylor R, Thielke R, Payne J, Gonzalez N, Conde JG. Research electronic data capture (REDCap)—a metadata-driven methodology and workflow process for providing translational research informatics support. *J Biomed Inform* 2009;42:377–81.
- Hoksbergen AW, Legemate DA, Csiba L, Csati G, Siro P, Fulesdi B. Absent collateral function of the circle of Willis as risk factor for ischemic stroke. *Cerebrovasc Dis* 2003;16:191–8.
- Van Raamt AF, Mali WP, Van Laar PJ, Van Der Graaf Y. The fetal variant of the circle of Willis and its influence on the cerebral collateral circulation. *Cerebrovasc Dis* 2006;22:217–24.
- Zhou H, Sun J, Ji X, Lin J, Tang S, Zeng J, Fan YH. Correlation between the integrity of the circle of Willis and the severity of initial noncardiac cerebral infarction and clinical prognosis. *Medicine* 2016;95:e2892.

- 17 Shaban A, Albright KC, Boehme AK, Martin-Schild S. Circle of Willis variants: fetal PCA. *Stroke Res Treat* 2013;2013:105937.
- 18 Hendrikse J, Hartkamp MJ, Hillen B, Mali WP, Van Der Grond J. Collateral ability of the circle of Willis in patients with unilateral internal carotid artery occlusion: border zone infarcts and clinical symptoms. *Stroke* 2001;32:2768–73.
- 19 Burlew CC, Biffi WL, Moore EE, Pieracci FM, Beauchamp KM, Stovall R, Wagenaar AE, Jurkovich GJ. Endovascular stenting is rarely necessary for the management of blunt cerebrovascular injuries. *J Am Coll Surg* 2014;218: 1012–17.
- 20 Cothren CC, Moore EE, Biffi WL, Ciesla DJ, Ray CE, Johnson JL, Moore JB, Burch JM. Anticoagulation is the gold standard therapy for blunt carotid injuries to reduce stroke rate. *Arch Surg* 2004;139:540–5. discussion 5–6.
- 21 Elgendy IY, Kumbhani DJ, Mahmoud A, Bhatt DL, Bavry AA. Mechanical thrombectomy for acute ischemic stroke: a meta-analysis of randomized trials. *J Am Coll Cardiol* 2015;66:2498–505.
- 22 Pierot L, Soize S, Benaissa A, Wakhloo AK. Techniques for endovascular treatment of acute ischemic stroke: from intra-arterial fibrinolytics to stent-retrievers. *Stroke* 2015;46:909–14.