

# Bilioptysis due to a single transcavitary thoracoabdominal gunshot wound

Jordan Nantais,<sup>1</sup> Graham Skelhorne-Gross,<sup>2</sup> Carolina Jimenez,<sup>2</sup> Najma Ahmed,<sup>2,3</sup> David Gomez <sup>2,3</sup>

<sup>1</sup>Division of Critical Care, University of Toronto, Toronto, Ontario, Canada

<sup>2</sup>Department of Surgery, University of Toronto, Toronto, Ontario, Canada

<sup>3</sup>Surgery, St Michael's Hospital, Unity Health Toronto, Toronto, Ontario, Canada

## Correspondence to

Dr David Gomez, St. Michael's Hospital, Toronto, ON M5B1W8, Canada; david.gomez@unityhealth.to

Revised 9 December 2019

Accepted 11 December 2019

## CASE SUMMARY

A 27-year-old man was transported to our trauma center after sustaining a single gunshot wound. On arrival, he was hemodynamically stable and neurologically intact, with a non-tender abdomen and negative FAST (focused assessment with sonography in trauma). Complete skin examination revealed a wound on his left hip and no additional injuries. CT demonstrated a trans-thoracoabdominal trajectory with a single projectile embedded in the right chest wall and suspected injuries to the duodenum, descending colon, pancreatic head, gall bladder, liver, and diaphragm (figure 1).

A trauma laparotomy was performed, and the patient was found to have gross disruption of the anterior first and second parts of the duodenum, distal common bile duct injury, perforation of the gall bladder, liver injury traversing segments 4b and 8, sigmoid mesocolon injury, right diaphragm perforation, and right hemopneumothorax. No definitive pancreatic duct injury was identified. Given ongoing hemodynamic and metabolic stability, definitive repair was completed, including right chest tube insertion, primary repair of the right diaphragm, cholecystectomy, primary duodenal repair, pyloric exclusion with Roux-en-Y gastrojejunostomy, hepaticojejunostomy, sigmoid mesocolon repair, and wide drainage for possible pancreatic injury.

Postoperatively, a pancreatic leak was noted, which resolved with medical treatment including total parenteral nutrition and a somatostatin analogue. Three weeks after the initial injury, the patient developed sudden respiratory distress with associated bilioptysis. Abdominal CT showed large, infected-appearing suprahepatic collections adjacent to the segment 8 liver injury and residual right pleural fluid. He underwent bronchoscopy, which demonstrated bile within the right bronchus, followed by laparotomy, perihepatic collection drainage, and right chest tube replacement. The bilioptysis persisted, although episodes were initially less frequent with lower output, and his respiratory failure resolved. Magnetic resonance cholangiopancreatography (MRCP) showed a segment 8 ductal injury in the liver which was communicating with the subphrenic fluid collection. Five weeks after the injury, he again developed severe respiratory distress with associated high-volume bilioptysis.

## WHAT WOULD YOU DO?

- Repeat laparotomy and fistulotomy.
- Right posterolateral thoracotomy and fistulotomy.

- Endoscopic retrograde cholangiopancreatography (ERCP) and biliary stent.
- Percutaneous transhepatic cholangiography (PTC) with drain placement.

## WHAT WE DID AND WHY

Decompression of the biliary tract via routine or double-balloon ERCP was unsuitable given the recent hepaticojejunostomy. PTC with drain placement as sole management was unlikely to be successful due to non-dilation of the biliary tract. Furthermore, the patient continued to decline rapidly with worsening respiratory failure requiring endotracheal intubation. Given these limitations, we thought that immediate operative intervention was warranted. We performed right posterolateral thoracotomy and took down an area of dense adherence between the right lower lobe and the previously repaired diaphragm, revealing an epithelialized tract with ongoing bilious output. A wedge resection of the lung was performed, followed by repair of the defect in the diaphragm with a bovine pericardial patch and wide drainage. Postoperatively, pleural bile leakage was persistent and the patient underwent PTC placement with internal/external drainage to decompress the biliary tree (figure 2). After this, the bilious drainage resolved, and all drains were eventually removed. There were no additional episodes of bilioptysis, and the remainder of his recovery was uneventful.

## DISCUSSION

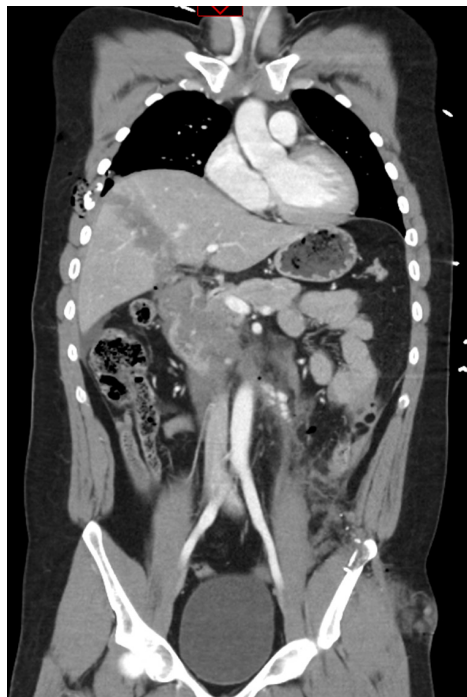Fistulization between the biliary system and the thoracic cavity is a rare condition that has been observed as a result of hepatic abscesses, pancreatitis, choledocholithiasis, neoplasms, iatrogenic injuries, and in rare circumstances trauma.<sup>1</sup> Infrequently, this process results in a direct connection from the biliary tract to the bronchial tree, referred to as bronchobiliary fistula (BBF).<sup>1-3</sup> Post-traumatic BBFs are extremely rare but have been noted to be more common in penetrating than blunt trauma.<sup>1,3</sup> Several factors likely contribute to BBF formation in trauma, including untreated diaphragmatic lacerations and inadequate drainage of liver injuries.<sup>4,5</sup>

Patients with BBF characteristically present with fever, cough, and bilioptysis, which is pathognomonic of the disease.<sup>1</sup> Secondary complications such as bronchiolitis, pneumonia, and respiratory failure are also common.<sup>1</sup> Various diagnostic modalities can be useful for diagnosing BBF, including CT, MRCP, ERCP, and scintigraphy.<sup>6,7</sup> ERCP is particularly effective at localizing the fistulous tract and

© Author(s) (or their employer(s)) 2020. Re-use permitted under CC BY-NC. No commercial re-use. See rights and permissions. Published by BMJ.

## To cite:

Nantais J, Skelhorne-Gross G, Jimenez C, et al. *Trauma Surg Acute Care Open* 2020;**5**:e000425.



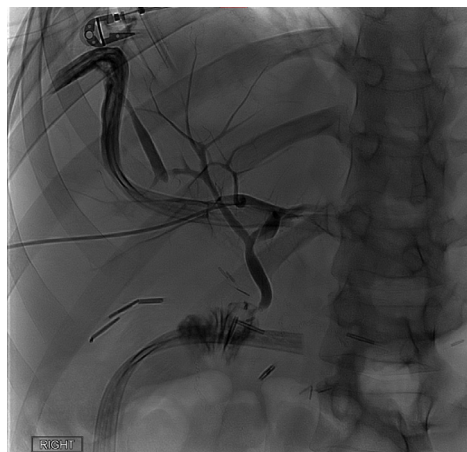
**Figure 1** CT of chest and abdomen showing tract of the projectile.

allows for simultaneous therapeutic intervention.<sup>6</sup> Interestingly, it has also been shown that the use of urine dipsticks to detect bilirubin in sputum may aid in making the diagnosis.<sup>8</sup>

An initial course of non-operative management appears appropriate in clinically stable patients, and typically includes pleural and perihepatic drainage, endoscopic or percutaneous biliary drainage, and administration of a somatostatin analogue.<sup>1, 2, 9-12</sup> When necessary, there is some consensus that the best operative approach is via thoracotomy, which facilitates the release of lung entrapment, fistula excision, decortication, and diaphragmatic closure.<sup>5, 13-16</sup> The method of diaphragmatic repair is controversial but includes primary closure with or without coverage with acellular dermal matrices or a vascularized tissue pedicle.<sup>14, 16</sup>

## CONCLUSION

BBF is rarely encountered, and important questions remain regarding its management. These include how to best select patients who may be successfully managed with non-operative



**Figure 2** Percutaneous Transhepatic Cholangiography showing bile leak.

therapy, how long this should be trialed before operative intervention is necessary, and what operative approach is most effective for treatment. Our case demonstrates the successful resolution of a complex BBF for which non-operative techniques were limited by anatomic constraints and rapid clinical deterioration.

**Contributors** JN, GS-G, CJ, NA: case management, article preparation. DG: guarantor, case management, article preparation. The corresponding author attests that all listed authors meet the authorship criteria and that no others meeting the criteria have been omitted.

**Funding** The authors have not declared a specific grant for this research from any funding agency in the public, commercial or not-for-profit sectors.

**Competing interests** None declared.

**Patient consent for publication** Extensive attempts to contact the patient for consent were unsuccessful. Communication was attempted both through his available contact information and family members. In keeping with BMJ consent and confidentiality protocol, all data are anonymized, and no identifying information is provided. CT and MRI have had all identifying text removed and have likewise been anonymized.

**Ethics approval** This submission was completed following appropriate ethics approval through the Research and Ethics Board of Unity Health Toronto.

**Provenance and peer review** Not commissioned; internally peer reviewed.

**Open access** This is an open access article distributed in accordance with the Creative Commons Attribution Non Commercial (CC BY-NC 4.0) license, which permits others to distribute, remix, adapt, build upon this work non-commercially, and license their derivative works on different terms, provided the original work is properly cited, appropriate credit is given, any changes made indicated, and the use is non-commercial. See: <http://creativecommons.org/licenses/by-nc/4.0/>.

## ORCID iD

David Gomez <http://orcid.org/0000-0002-0926-2547>

## REFERENCES

- Liao G-Q, Wang H, Zhu G-Y, Zhu K-B, Lv F-X, Tai S. Management of acquired bronchobiliary fistula: a systematic literature review of 68 cases published in 30 years. *World J Gastroenterol* 2011;17:3842-9.
- Stowers J, Hill J, Straus J. Traumatic bronchobiliary fistula. *Am Surg* 2014;80:E182-4.
- Banerjee N, Rattan A, Priyadarshini P, Kumar S. Post-Traumatic bronchobiliary fistula. *BMJ Case Rep* 2019;12:e228294.
- Oparah SS, Mandal AK. Traumatic thoracobiliary (pleurobiliary and bronchobiliary) fistulas: clinical and review study. *J Trauma* 1978;18:539-44.
- Coselli JS, Mattox KL. Traumatic bronchobiliary fistula. *J Trauma* 1983;23:161-2.
- Oettl C, Schima W, Metz-Schimmerl S, Függer R, Mayrhofer T, Herold CJ. Bronchobiliary fistula after hemihepatectomy: cholangiopancreatography, computed tomography and magnetic resonance cholangiography findings. *Eur J Radiol* 1999;32:211-5.
- Parghane RV, Phulsunga RK, Gupta R, Basher RK, Bhattacharya A, Mittal BR. Usefulness of Tc99m-mebrofenin hepatobiliary scintigraphy and single photon emission computed tomography/computed tomography in the diagnosis of Bronchobiliary fistula. *World J Nucl Med* 2017;16:317-9.
- Lee J, Jung SM, Lee Y, Kim S-Y. Anesthetic management for a patient with bronchobiliary fistula after pancreaticoduodenectomy: a case report. *Medicine* 2019;98:e15694.
- Liao G-Q, Wang H, Hu Q-H, Tai S. A successful treatment of traumatic bronchobiliary fistula by endoscopic retrograde biliary drainage. *Chin J Traumatol* 2012;15:59-61.
- Anderson RL. Traumatic bronchobiliary fistulae. *Am Surg* 1961;27:431-6.
- Ball CG, Trexler S, Rajani RR, Vercruyse G, Feliciano DV, Nicholas JM. Importance of liver drainage in biliary-bronchopleural fistula resulting from thoracoabdominal gunshot injury. *Can J Surg* 2009;52:E12-13.
- Railo M, Salmela K, Isoniemi H, Kyllönen L, Höckerstedt K. Use of somatostatin in biliary fistulas of transplanted livers. *Transplant Proc* 1992;24:391-3.
- Mehrzad H, Aziz A, Mangat K. Transhepatic embolisation of a traumatic bronchobiliary fistula: a novel approach. *BMJ Case Rep* 2012;2012.
- Chua HK, Allen MS, Deschamps C, Miller DL, Pairolero PC. Bronchobiliary fistula: principles of management. *Ann Thorac Surg* 2000;70:1392-4.
- Haciibrahimoglu G, Solak O, Olcmen A, Bedirhan MA, Solmazer N, Gurses A. Management of traumatic diaphragmatic rupture. *Surg Today* 2004;34:111-4.
- Gandhi N, Kent T, Kaban JM, Stone M, Teperman S, Simon R. Bronchobiliary fistula after penetrating thoracoabdominal trauma: case report and literature review. *J Trauma* 2009;67:E143-5.