




# Severe traumatic scalp avulsion requiring an uncommon reconstruction: omental free tissue transfer flap

Alyssa Catherine MacLean <sup>1</sup>, Adil Ladak,<sup>2</sup> Ryan Snelgrove,<sup>1</sup> Haili Wang,<sup>1</sup> Hollie Power <sup>2</sup>, Nori L Bradley <sup>1</sup>

<sup>1</sup>Division of General Surgery, University of Alberta, Edmonton, Alberta, Canada

<sup>2</sup>Division of Plastic Surgery, University of Alberta, Edmonton, Alberta, Canada

## Correspondence to

Dr Alyssa Catherine MacLean; [acmaclea@ualberta.ca](mailto:acmaclea@ualberta.ca)

## CASE DESCRIPTION

A 29-year-old woman presented to our level 1 trauma center following blunt head trauma from agricultural equipment. During advanced trauma life support assessment, secondary survey revealed a near-total scalp degloving injury, encompassing the forehead and circumferential scalp to the superior nuchal line (figure 1A). The avulsed scalp was severely damaged and fragmented, precluding immediate reimplantation. The patient underwent multiple operative debridements and diligent wound management with saline-soaked dressings, then negative pressure wound therapy once the wound base was clean. Despite elevation of local periosteal and temporalis muscle advancement flaps, incomplete calvarial coverage rendered primary skin graft reconstruction impossible. The patient continued to have exposed calvarium, necessitating vascularized soft tissue coverage<sup>1</sup> (figure 1B).

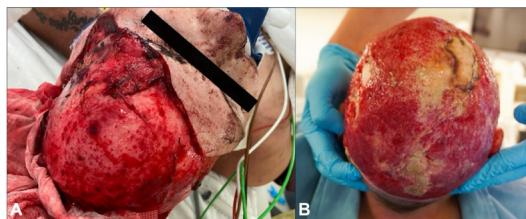
## WHAT WOULD YOU DO NEXT?

- Burr the outer table of the calvarium, negative pressure wound therapy, then eventual split-thickness skin graft
- Anterolateral thigh free flap ± skin graft
- Omental free flap with split-thickness skin graft
- Latissimus dorsi pedicled flap with split-thickness skin graft

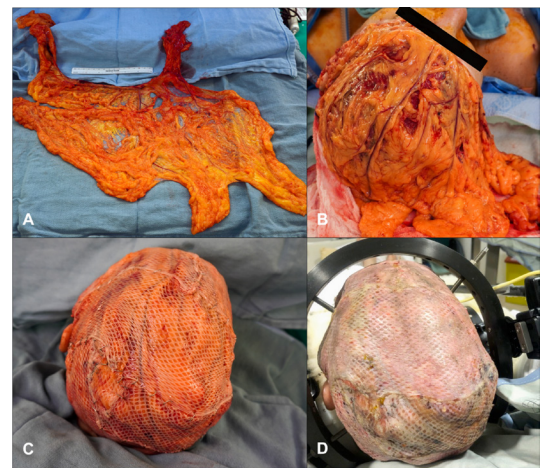
## WHAT WE DID AND WHY

- Omental free flap with split-thickness skin graft.

We chose to perform laparoscopic retrieval of autologous omentum to use as a vascularized free tissue transfer flap (free flap). The omental free flap served as a vascularized bed for a split-thickness skin graft to achieve total coverage of the scalp defect.



**Figure 1** (A) Severe circumferential scalp avulsion injury on ATLS secondary survey in trauma bay. (B) Exposed calvarium persists despite multiple operative debridements and elevation of local advancement flaps. ATLS, advanced trauma life support.



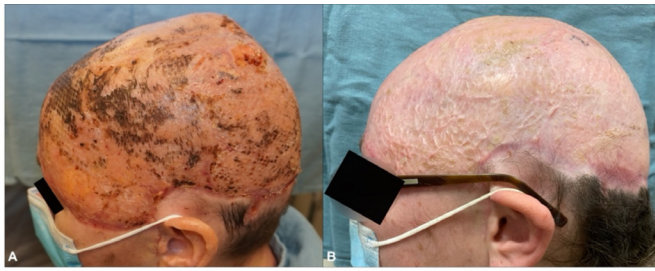
**Figure 2** (A) Autologous omental harvest with preservation of the right gastroepiploic vessels. (B) Omental free flap transfer to the skull, providing full coverage of the scalp defect. (C) Omental flap supporting meshed split-thickness skin graft (secured with skin staples and fibrin glue). (D) Neurosurgical halo device to offload posterior flap and skin graft for optimal healing.

Omental free flaps have been described for reconstructive purposes in craniofacial and pharyngolaryngeal surgical oncology, plastic and reconstructive surgery, and in the context of destructive or persistent infections in various anatomic regions. However, omental flaps have been infrequently used for reconstruction following traumatic injuries, and their use in an acute setting is rarely described in the trauma literature. Our plastic surgery colleagues recommended vascularized omentum as a free tissue transfer flap to the calvarium as the best reconstructive option in this patient for multiple reasons: the large surface area requiring coverage, the thin profile of the flap, and the minimal associated donor site morbidity. Positive patient factors—slim body habitus, no prior abdominal operations or procedures, and hemodynamic stability—facilitated a minimally invasive approach to autologous omental harvest.

In a combined operative procedure, the plastic surgery team prepared the skull and the left superficial temporal vessels for free flap transfer, while the acute care surgeons performed laparoscopic omentectomy with careful identification and preservation of the right gastroepiploic artery and vein (figure 2A). The omentum was removed via

© Author(s) (or their employer(s)) 2022. Re-use permitted under CC BY-NC. No commercial re-use. See rights and permissions. Published by BMJ.

**To cite:** MacLean AC, Ladak A, Snelgrove R, et al. *Trauma Surg Acute Care Open* 2022;**7**:e000895.



**Figure 3** Outpatient follow-up reveals complete coverage of the scalp defect and an aesthetic contour at 4 weeks (A) and 9 months (B) postoperatively.

laparoscopic retrieval bag, primed with heparinized saline, and microvascular anastomosis of right gastroepiploic to left superficial temporal vessels was completed by the plastic surgery team. Indocyanine green confirmed perfusion of the flap, and non-illuminating segments were resected. The omental flap was inset along the borders of the scalp defect (figure 2B) and trimmed to fit. A split-thickness skin graft was then harvested from the patient's left thigh and meshed at a ratio of 1:1.5. The skin graft was placed over the omental flap and secured with skin staples and fibrin glue (figure 2C). At the end of the procedure, the neurosurgery team applied a halo device to offload the posterior skull for optimal flap and graft healing (figure 2D). Graft take was excellent, and outpatient follow-up confirmed successful coverage of the entire scalp defect and an aesthetic scalp contour at 4 weeks (figure 3A) and 9 months (figure 3B) postoperatively.

## CONCLUSION

Traumatic scalp avulsion injuries can cause significant morbidity and psychosocial impact. Extensive surface area of exposed calvarium and limited availability of vascularized tissues for

coverage complicate definitive wound management. Omental harvest for free tissue transfer flap has been described in the plastic surgery literature with excellent results. Given its effective defect coverage and aesthetic overall appearance, we recommend laparoscopic retrieval of autologous omentum for microvascular free flap reconstruction be included in a multi-disciplinary wound management algorithm for severe traumatic scalp avulsion injuries in trauma and acute care settings.

**Twitter** Hollie Power @HolliePowerMD and Nori L Bradley @BradleyNori

**Contributors** ACM and NLB conceptualized the article, which ACM drafted and with editorial and content contributions from AL, RS, HW, HP and NLB throughout multiple revisions and updates.

**Funding** The authors have not declared a specific grant for this research from any funding agency in the public, commercial or not-for-profit sectors.

**Competing interests** None declared.

**Patient consent for publication** Obtained.

**Ethics approval** This study involves human participants but did not undergo formal ethics review as it is a case report, and participants gave informed consent to participate in the study before taking part.

**Provenance and peer review** Not commissioned; internally peer reviewed.

**Open access** This is an open access article distributed in accordance with the Creative Commons Attribution Non Commercial (CC BY-NC 4.0) license, which permits others to distribute, remix, adapt, build upon this work non-commercially, and license their derivative works on different terms, provided the original work is properly cited, appropriate credit is given, any changes made indicated, and the use is non-commercial. See: <http://creativecommons.org/licenses/by-nc/4.0/>.

## ORCID iDs

Alyssa Catherine MacLean <http://orcid.org/0000-0001-7076-5875>

Hollie Power <http://orcid.org/0000-0003-1131-5940>

Nori L Bradley <http://orcid.org/0000-0001-6966-1964>

## REFERENCE

- 1 MacLean A, 2021. Autologous omental harvest for microvascular free flap reconstruction of a severe traumatic scalp degloving injury: a case report. Poster presented at: trauma association of Canada annual scientific meeting; Apr 12-16.