

Novel repair of costal margin rupture with preoperative 3D planning

Casey T Walk , Gregory R Semon

Department of Surgery, Wright State University Boonshoft School of Medicine, Dayton, Ohio, USA

Correspondence to

Casey T Walk; casey.walk@wright.edu

WHAT WOULD YOU DO?

This is a 32-year-old man involved in a motor vehicle crash in 2019 with chronic left-sided rib pain since. He was initially treated with physical therapy and medical management with no improvement. CT imaging in 2021 noted displaced left lateral seventh and eighth ribs, noted chest wall deformity, and when three-dimensional (3D) reconstruction of his ribs was created, this noted a left-sided costal margin rupture at the sixth and seventh ribs ([figure 1](#)).

WHAT WE DID AND WHY

Due to this patient's ongoing pain limiting his lifestyle, we opted to attempt a novel surgical intervention. The 3D printing of his ribs was created, and a custom rib plate, a sternal T plate 2mm thick, was molded preoperatively to the contour of his ribs as they had become deformed since the accident ([figure 2](#)).

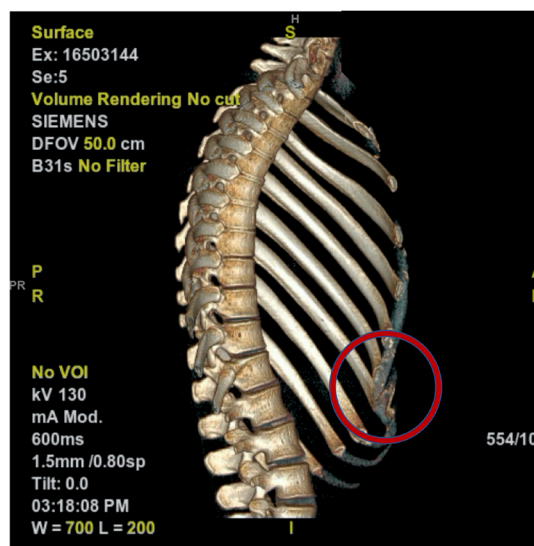
He was brought to the operating room and an incision was made over his left anterior seventh rib, and the costal margin rupture was exposed along with the appropriate amount of space on the lateral rib for placement of the plate. The custom molded plate was brought to the field and fit into place, secured with sternal screws, and inspected to be in adequate position ([figure 3](#)). The chest wall felt intact with improvement in deformity and strength. The patient had no complications and was discharged home on postoperative day 1.

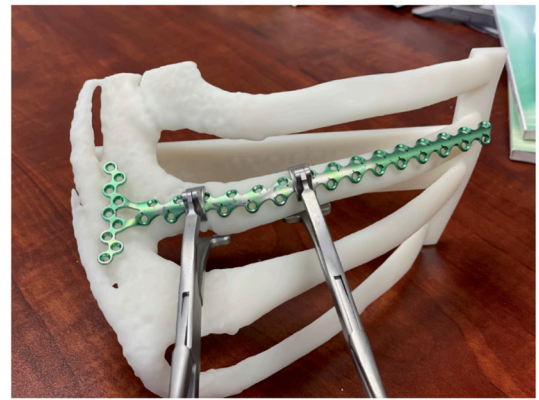

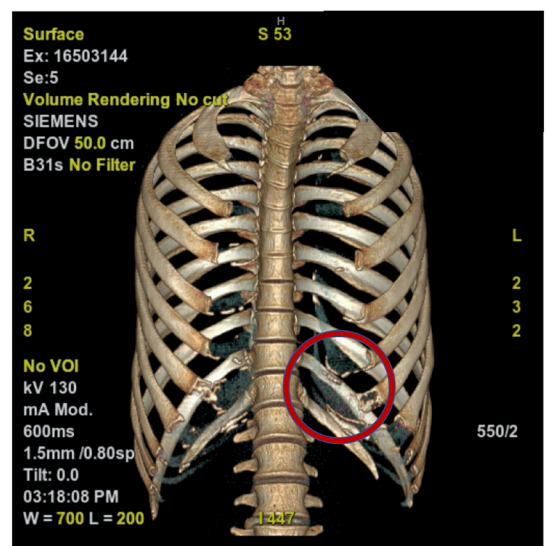
Figure 2 Preoperative planning 3D printed chest wall to pre-mold rib plate.

He was followed up 2 weeks postoperatively with resolution of his chronic pain and was well healed. Informed consent was waived by the Institutional Review Board but discussed with the patient during his postoperative visits, and he agreed with the publication.

Rib plating for acute rib fractures is well researched and practiced in the trauma setting for specific indications, although the research on costal margin rupture is limited. This is a presentation of a successful costal margin rupture repair managed via custom rib plating using preoperative 3D planning. This has been shown to be an effective and



A



B

Figure 1 Preoperative 3D reconstruction CT imaging with circled costal margin rupture causing chest wall deformity. A- Sagittal view. B- Coronal view.

© Author(s) (or their employer(s)) 2022. Re-use permitted under CC BY-NC. No commercial re-use. See rights and permissions. Published by BMJ.

To cite: Walk CT, Semon GR. *Trauma Surg Acute Care Open* 2022;**7**:e001001.

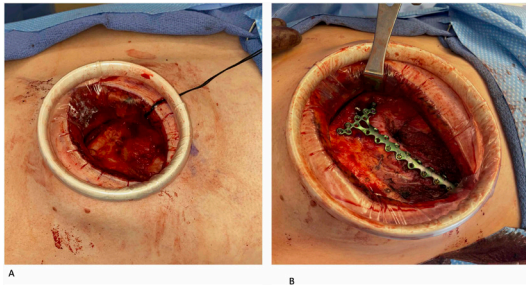


Figure 3 Intraoperative imaging. A- Exposure prior to rib plating. B- Completed rib plating with pre-molded rib plate secured into place noting to traverse the costal margin rupture with T portion secured on costal margin.

safe approach to surgical management of costal margin rupture and should be considered in the future in appropriate patients.

In conclusion, this novel approach to repair costal margin rupture was successful and has demonstrated feasibility. We

recommend offering this repair option on a case-by-case basis as there is limited research.

Contributors CTW—article preparation, writing and editing. GRS—conception, article editing and final approval.

Funding The authors have not declared a specific grant for this research from any funding agency in the public, commercial or not-for-profit sectors.

Competing interests None declared.

Patient consent for publication Not required.

Provenance and peer review Not commissioned; internally peer reviewed.

Open access This is an open access article distributed in accordance with the Creative Commons Attribution Non Commercial (CC BY-NC 4.0) license, which permits others to distribute, remix, adapt, build upon this work non-commercially, and license their derivative works on different terms, provided the original work is properly cited, appropriate credit is given, any changes made indicated, and the use is non-commercial. See: <http://creativecommons.org/licenses/by-nc/4.0/>.

ORCID iD

Casey T Walk <http://orcid.org/0000-0001-5275-0047>