

Management of the perforated duodenal diverticulum

William Ian McKinley ,¹ Trever Symalla,² Andrew Benjamin¹¹Biological Sciences Division, University of Chicago, Chicago, Illinois, USA²Surgical Operations Squadron, David Grant Medical Center, Travis AFB, California, USA**Correspondence to**
Dr William Ian McKinley;
William.Mckinley@
uchicagomedicine.org**CASE DESCRIPTION**

A woman in her 70s presented to the emergency department after having sudden-onset right lower quadrant pain 2 hours earlier. She noted the pain to be 10/10 in severity, non-radiating, and cramping in character. Vitals and labs including a basic metabolic panel and complete blood count were within normal limits; however a lactic acid level was elevated at 3.4 (normal <2). A CT scan was performed with findings of free air and fluid in the lesser sac, a significantly distended stomach, and retroperitoneal debris (figure 1). General surgery was consulted at this time; the patient was found to be distended, tympanitic, and peritonitic on examination. Intravenous fluid resuscitation and broad-spectrum antibiotics were initiated. She was taken directly to the operating room for operative intervention, given her examination and imaging findings. Laparoscopy was performed with minimal findings, though a large collection of fluid was seen in the retroperitoneum surrounding the duodenum. Suspicion of a posterior duodenal perforation was high, and therefore the prior laparoscopy was converted to an exploratory laparotomy. The right colon was mobilized and inspected, and no defect was identified. A Kocher maneuver was performed and copious bilious fluid was encountered. A 3 cm defect was evident on the lateral aspect of the second portion of the duodenum (figure 2). On further mobilization, a very redundant duodenal diverticulum (DD) was revealed.

WHAT WOULD YOU DO NEXT?

- Wide local drainage and temporary abdominal closure
- Primary repair of the defect.
- Stapled diverticulectomy.
- Pancreaticoduodenectomy

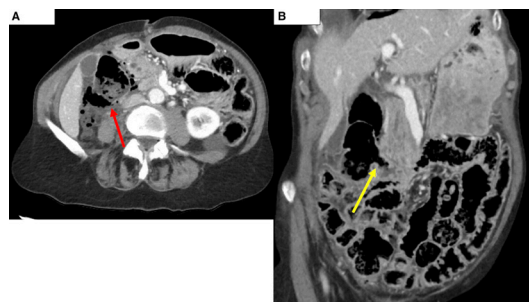


Figure 1 (A) Red arrow designating defect in DD seen on axial CT series. (B) Yellow arrow identifying the neck of the DD on coronal CT series. DD, duodenal diverticulum.

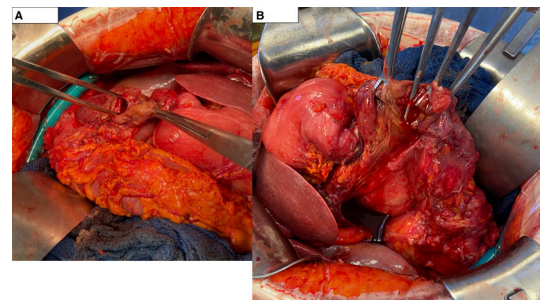


Figure 2 (A) Initial view of defect in the diverticulum. (B) Lateral view of the duodenal diverticulum after full Kocherization of the duodenum.

C) Stapled diverticulectomy

A bowel clamp was placed across the anticipated staple line. Esophagogastroduodenoscopy was performed, and the scope passed to the third portion of the duodenum without difficulty; the ampulla was identified in the second portion and was found to be opposite the diverticulum. A stapled diverticulectomy was performed to eliminate thin, redundant tissue, and subsequent leak test was negative. A feeding tube was passed distal to the ligament of Treitz, and a nasogastric tube was placed. A Blake drain was placed near the staple line and left to gravity. Postoperatively, she was transferred to the intensive care unit for monitoring and ongoing resuscitation. She completed a 4-day course of antibiotics, and tube feeds were initiated on postoperative day 3. An upper gastrointestinal study on postoperative day 5 demonstrated no leak but was noted to have delayed contrast transit through the duodenum which was suspected to be related to postsurgical edema (figure 3). A delayed abdominal radiograph demonstrated passage of contrast into the distal small bowel. Her nasogastric and feeding tubes were removed, and a clear liquid diet was initiated. On postoperative day 6, she was advanced to a regular diet; her abdominal drain was removed; and she was discharged home.

First described by French pathologist Auguste Chomel, DDs were historically thought to be a relatively rare entity; more recent series based on autopsy and endoscopic retrograde cholangiopancreatography (ERCP) suggest the prevalence is as high as 22%.¹ DD may be primary (ie, congenital) or secondary (ie, acquired, thought to be related to herniation through the muscular defect occurring at the entrance of large vessels supplying the bowel), and variations in the relevant anatomy are also encountered, especially as they relate to the duodenal papilla.² Once discovered, treatment strategies for perforated DD depend on the

© Author(s) (or their employer(s)) 2023. Re-use permitted under CC BY-NC. No commercial re-use. See rights and permissions. Published by BMJ.

To cite:

McKinley WI, Symalla T, Benjamin A. *Trauma Surg Acute Care Open* 2023;**8**:e001087.

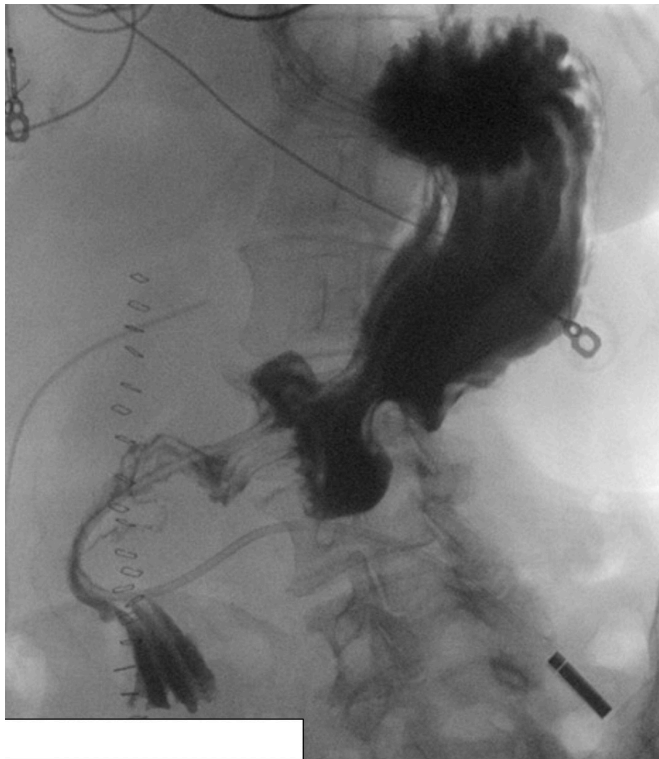

Figure 3 Upper gastrointestinal study.

patient's presentation, physiology, and location/size of the abnormality.

Non-operative treatment with intravenous antibiotics and bowel rest has been well described and successful in a subset of patients who are stable and without peritonitis or in patients with significant comorbidities who are poor operative candidates. In the most recent review by Kapp *et al*, 34% of patients were initially treated non-operatively, continuing a growing trend in the modern era.² Patients being managed non-operatively should be closely monitored; clinical deterioration mandates surgical intervention.

A variety of operative approaches have been described, including damage control operation in septic patients (ie, lavage, drainage, and pyloric exclusion), diverticulectomy, duodenectomy, and even pancreaticoduodenectomy in rare instances.²

Endoscopic therapy and percutaneous drains have been successfully used as adjuncts in select circumstances as well.

Although DDs have been found to be more prevalent over time, complications, including perforation, remain exceptionally rare. Only 163 cases of perforation have been reported in the literature to date, with mortality rates of series ranging from 6% to 33%.^{1,3} Most perforations present with free retroperitoneal air and fluid on CT imaging, as was notable in this case. In conclusion, perforated DD is an exceptionally rare but serious diagnosis with relatively high mortality. Treatment is primarily operative; however, non-operative treatment and adjuncts such as endoscopy and percutaneous drainage have been used in select circumstances.

Contributors All authors were substantially involved in the writing of this article. All participated in the relevant clinical care and provided significant writing and editing for the document.

Funding The authors have not declared a specific grant for this research from any funding agency in the public, commercial or not-for-profit sectors.

Competing interests None declared.

Patient consent for publication Consent obtained directly from patient(s).

Ethics approval This study involves human participants but was not approved by an institutional review board (IRB) because it was a case report and falls outside of approval by an IRB. Consent for use of information was obtained directly from the patient involved. The participants gave informed consent to participate in the study before taking part.

Provenance and peer review Not commissioned; internally peer reviewed.

Open access This is an open access article distributed in accordance with the Creative Commons Attribution Non Commercial (CC BY-NC 4.0) license, which permits others to distribute, remix, adapt, build upon this work non-commercially, and license their derivative works on different terms, provided the original work is properly cited, appropriate credit is given, any changes made indicated, and the use is non-commercial. See: <http://creativecommons.org/licenses/by-nc/4.0/>.

ORCID iD

William Ian McKinley <http://orcid.org/0000-0002-3487-7738>

REFERENCES

- 1 Haboubi D, Thapar A, Bhan C, Oshowo A. Perforated duodenal diverticulae: importance for the surgeon and gastroenterologist. *BMJ Case Rep* 2014;2014:bcr2014205859.
- 2 Kapp JR, Müller PC, Gertsch P, Gubler C, Clavien P-A, Lehmann K. A systematic review of the perforated duodenal diverticula: lessons learned from the last decade. *Langenbecks Arch Surg* 2022;407:25–35.
- 3 Costa Simões V, Santos B, Magalhães S, Faria G, Sousa Silva D, Davide J. Perforated duodenal diverticulum: surgical treatment and literature review. *Int J Surg Case Rep* 2014;5:547–50.