

# Rib fragment compressing aorta in patient with chest and spinal injuries

Zoran Dakic , Marko Kantar, Bojan Bjelosevic, Branko Strbac, Miroslav Stranatic, Radomir Jerkic

Thoracic Surgery Clinic,  
University Clinical Centre of the  
Republic of Srpska, Banja Luka,  
Bosnia and Herzegovina

## Correspondence to

Dr Zoran Dakic; dakiczorann@gmail.com

## CASE PRESENTATION

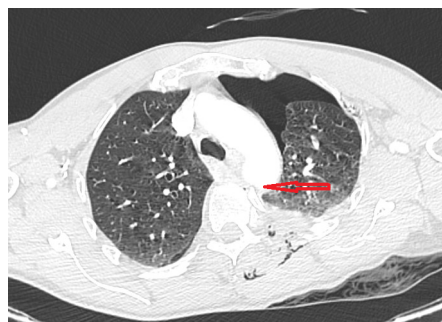A logger in his 60s was referred to our hospital with chest, spine, and lower limb injuries caused by a falling tree. He complained of chest and lumbar pain, and a painful and swollen right ankle. At admission, Glasgow Coma Scale score was 15, and the patient was respiratory and hemodynamic stable (blood pressure 160/70 mm Hg; pulse 85 bpm; oxygen saturation 96%). He had no history of chronic diseases. CT scan revealed multiple rib fractures on the left side (fourth–eighth ribs had multifragmental fractures with dislocation). The fracture fragment of the fourth and fifth ribs was intrathoracically displaced, compressing the posterior wall of the thoracic aorta ([figure 1](#)). There were also signs of left scapular fracture, traumatic hemopneumothorax, and signs of pulmonary contusion. CT scan also showed an unstable multifragmental compressive fracture of the L4 vertebra. The patient had also a right bimalleolar fracture.

## WHAT WOULD YOU DO?

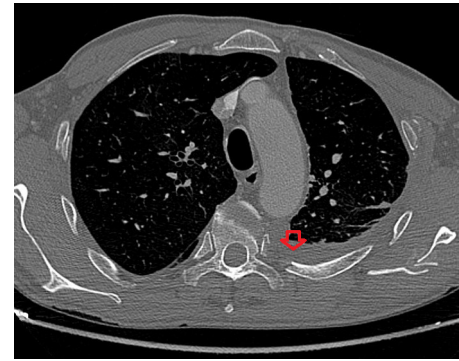
1. Chest drainage and pain management.
2. Anterior and posterior reduction and surgical stabilization of multifragmental rib fractures.
3. Posterior resection of rib fragments compressing aorta alongside anterior stabilization of multifragmental rib fractures.

## WHAT WE DID AND WHY?

After initial chest drainage, we repeated a CT scan and there were still signs of the fourth and fifth ribs compressing the posterior wall of the aorta. We decided to perform thoracotomy and rib resection of the posterior fragments of the fourth and fifth ribs that were in close contact with the aorta. Stielle-Giertz rib shares were very useful for resecting posterior rib fragments. Anterior fractures

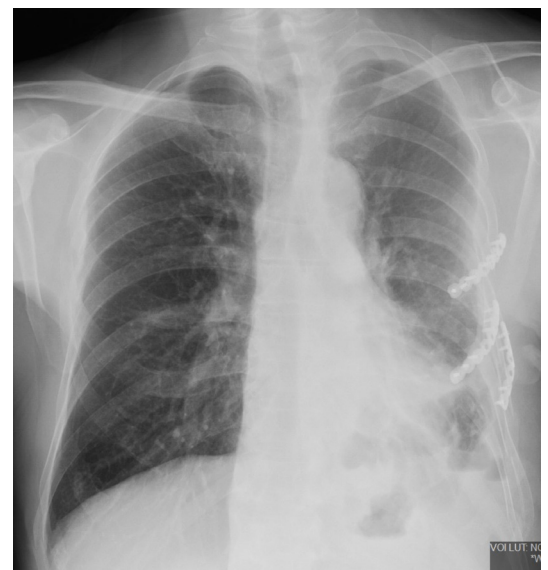

**Figure 1** Initial CT scan with rib fragment compressing the posterior wall of the aorta.



**Figure 2** CT scan before discharge, showing resected posterior part of the fourth rib.

of the fourth, fifth, and sixth ribs were stabilized using three metal plates. Due to the spinal injury, we used a surgical approach through left anterior thoracotomy with the patient in the supine position. Reduction and stabilization of posterior fragments of the fourth and fifth ribs would have demanded a decubital position, and in our case, that position was limited due to vertebral injury. Also, the posterior rib fracture was very close to the vertebra. Four days after the thoracotomy, L4 vertebral and right bimalleolar fractures were stabilized by orthopedic surgeons. Two weeks after thoracotomy, signs of thoracotomy wound infection and pleural effusion accumulation were registered on the left side on the



**Figure 3** Chest radiography before discharge, showing plated anterior parts of fractured ribs.

© Author(s) (or their employer(s)) 2023. Re-use permitted under CC BY-NC. No commercial re-use. See rights and permissions. Published by BMJ.

**To cite:** Dakic Z, Kantar M, Bjelosevic B, et al. *Trauma Surg Acute Care Open* 2023;**8**:e001261.

control CT scan. Another chest drainage was applied and the thoracotomy wound was treated with a vacuum-assisted closure (VAC) system and antibiotics according to the antibiogram. The chest drain was removed 6 days after drainage. Seven days after applying, VAC system was removed and the wound was closed with skin sutures. Further treatment was uneventful and the patient was discharged 1 month after admission (figures 2 and 3).

## DISCUSSION

Blunt chest trauma is very common and there is a significant percentage of people who died in the first hours after the accident. Consequently, it is vitally important to search for early clinical and radiological signs of potentially severe injury. Appropriate treatment could furthermore lead to a better survival of injured patients. Patients with blunt chest trauma often have fractured ribs and associated injuries to the adjacent organs. The number and type of rib fractures, presence of hemopneumothorax and lung contusions, diaphragm, spleen and liver injuries, comorbidities, and age could increase mortality. Although rarely, rib fractures with intrathoracic displacement of bone fragments can cause perforation of the aorta or other mediastinal organs. Aortic laceration in those circumstances could lead to extremely high mortality in the first hours after injury. Early recognition of such a life-threatening injury in a stable patient could prevent major bleeding due to potential aortic rupture. Treatment is a bit challenging when the patient has cranial and spinal injuries.

Considering optimal strategy, especially patient position, techniques, and available instruments may give good results.

**Contributors** ZD is guarantor and was responsible for planning, conceptualization, writing of the original draft, reviewing, and editing. MK was responsible for conceptualization and for supervision. BB, BS, MS, and RJ were responsible for conceptualization and editing.

**Funding** The authors have not declared a specific grant for this research from any funding agency in the public, commercial or not-for-profit sectors.

**Competing interests** None declared.

**Patient consent for publication** Not applicable.

**Ethics approval** The Ethics Committee of the University Clinical Center of the Republic of Srpska approved this study in document with ID number: 01-19-381-2/23. Our Ethics Committee uses ICH-GCP (International Conference on Harmonisation of technical requirements for registration of pharmaceuticals for human use-Guideline for Good Clinical Practice) standards.

**Provenance and peer review** Not commissioned; internally peer reviewed.

**Data availability statement** Data are available in a public, open access repository.

**Open access** This is an open access article distributed in accordance with the Creative Commons Attribution Non Commercial (CC BY-NC 4.0) license, which permits others to distribute, remix, adapt, build upon this work non-commercially, and license their derivative works on different terms, provided the original work is properly cited, appropriate credit is given, any changes made indicated, and the use is non-commercial. See: <http://creativecommons.org/licenses/by-nc/4.0/>.

## ORCID iD

Zoran Dakic <http://orcid.org/0009-0009-9046-7504>