

# Blunt thoracic aortic injury diagnosis and management: two decades of innovation from Memphis

Kimberly A Davis 

Division of General Surgery,  
Trauma and Surgical Critical  
Care, Yale School of Medicine,  
New Haven, Connecticut, USA

## Correspondence to

Dr Kimberly A Davis; kimberly.davis@yale.edu

Received 10 January 2023  
Accepted 20 February 2023

## ABSTRACT

In recognition of Dr Timothy Fabian's sentinel contributions to the field of trauma surgery, this review highlights his contributions to the diagnosis and management of blunt thoracic aortic injury and places his contributions into context relative to current practice.

## SETTING THE STAGE

In a groundbreaking publication in *Circulation* in 1958, Dr Loren Parmley, a pathologist at Walter Reed Army Hospital, described 275 patients with 'non-penetrating injury of the aorta', now more commonly known as blunt thoracic aortic injury (BAI).<sup>1</sup> The findings noted in that sentinel article drove many of the subsequent advances in the diagnosis and management of BAI. Dr Parmley noted that this was a highly lethal injury pattern as only 14% of patients reached the hospital alive and that in-hospital rupture was common (figure 1). He highlighted the need for prompt recognition and surgical therapy. Interestingly, only 32% of the initial survivors had the diagnosis of BAI made prior to rupture, as the most common diagnostic modality at the time was chest radiograph. In fact, Dr Parmley noted that diagnostic accuracy could be improved with the use of retrograde aortography to delineate the extent of the injury and assist with surgical planning.<sup>1 2</sup>

## FIRST DECADE OF MEMPHIS CONTRIBUTIONS (1990–2000)

As the experience with surgical repair of BAIs increased, so did the recognition that ischemic myelopathy resulting in complete or partial paraplegia was a frequent complication of aortic cross clamping due to the disruption of arterial flow through the artery of Adamkiewicz. In 1995, Drs Pate, Fabian, and Walker reported on early experience with partial cardiopulmonary bypass to augment retrograde aortic blood flow as an adjunct to aortic replacement, thus preventing spinal cord ischemia and decreasing the paraplegia rate to less than 10%. They did note that 15% of patients with significant intracranial injury had worsened bleeds after the heparinization needed for bypass.<sup>3</sup> This report was followed by a second the same year, noting that with aggressive medical management to decrease aortic wall stress (beta blockade and vasodilation), many patients could be successfully managed with delayed surgical intervention to repair their aorta, thus mitigating concerns

regarding systemic anticoagulation in the poly-trauma patient.<sup>4</sup>

Concurrent with their focus on improving clinical outcomes in patients with BAI was an interest in better diagnostic modalities. Transesophageal echocardiography (TEE) has been described as a potential non-invasive diagnostic modality, recognizing the challenges inherent in the technology, including inadequate visualization of the aortic arch and its branches and the operator dependency and learning curve associated with the diagnosis of a relatively uncommon injury. A prospective analysis of TEE for the diagnosis of BAI in 34 patients during a 15-month time period ending in June of 1994 was published in 1996 comparing TEE to aortography. The authors noted a sensitivity and specificity of TEE of 57% and 91%, significantly lower than those of aortography.<sup>5</sup>

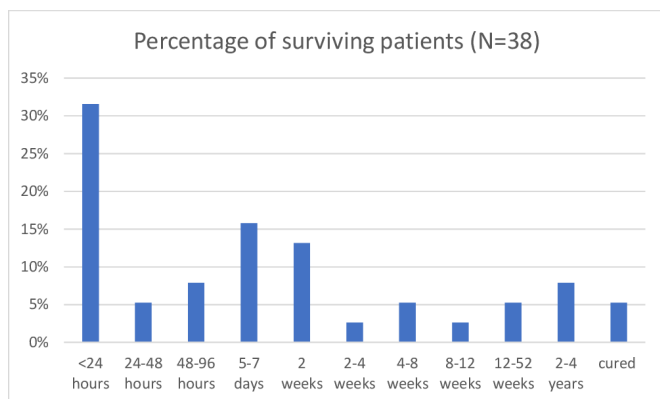
One of Dr Parmley's pathological observations noted that 7.6% of injuries were not full thickness injuries and involved only the intima or the media. These findings account for the occasionally normal radiographs of patients with aortic injury and highlighted the need for better diagnostic modalities. One of the initial reports detailing the effectiveness of helical CT scanning for the diagnosis of BAI was published in 1995. Twenty-one BAIs were identified, ranging from subtle intimal flaps to complete transections during 1 year, ending in September 1994. All patients underwent confirmatory aortography. Dr Gavant and colleagues reported a sensitivity of 100% (better than aortography at 94%) but lower specificity (81.7% for CT vs 96.3% for aortography).<sup>6</sup>

To further evaluate the diagnosis and surgical management of BAI, the American Association for the Surgery of Trauma designed a landmark multicenter prospective study of 274 patients with BAI during a 30-month period ending in June 1996 who survived long to hospital admission.<sup>7</sup> This article, of which Dr Fabian was the lead author, published in 1997, not only described the radiographical findings of BAI but also reported on the outcomes from surgical repair, stressing the high paraplegia rates of direct repair without bypass, and the use of the centrifugal pump to improve outcomes, which decreased paraplegia rates from the 16.4% rate with clamp-and-sew techniques to 2.9%.

I joined the team in Memphis in 1996 as a fellow in surgical critical care. One of my projects was to review the prior 4 years of patients with BAI, totaling 71 patients, most of whom underwent both

© Author(s) (or their employer(s)) 2023. Re-use permitted under CC BY-NC. No commercial re-use. See rights and permissions. Published by BMJ.

**To cite:** Davis KA. *Trauma Surg Acute Care Open* 2023;**8**:e001084.

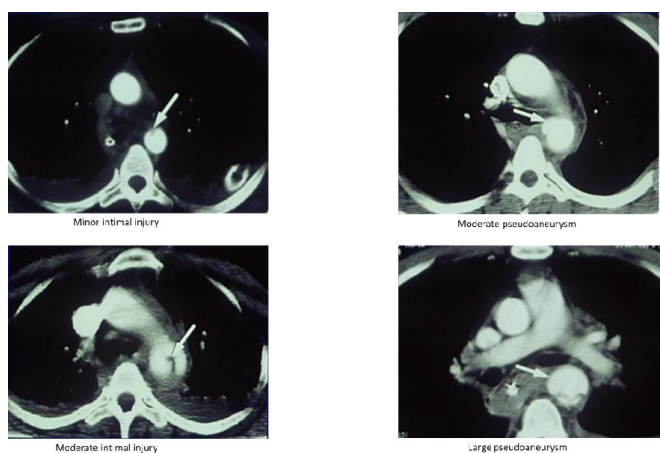


**Figure 1** Survival after blunt aortic injury for patients admitted to the hospital. Adapted from Parmley *et al.*<sup>1</sup>

helical CT scans and aortography (83%) for diagnosis of their injuries, which ranged in severity from intimal flaps to complete transections with false lumens.<sup>8</sup> Based on CT findings, we graded these injuries as mild, moderate, and severe. Representative CT images of BAI are demonstrated in figure 2. We confirmed similar sensitivity and specificity for CT as the prior study by Dr Gavant and colleagues.<sup>6</sup> Most patients (76%) were medically managed with beta blockade or a combination of beta blockers and nitroprusside. Those not managed medically were either hemodynamically normal or unstable. There were no complications associated with medical management and no in-hospital ruptures. Although most patients underwent immediate aortic repair, several had delayed repair due to either pulmonary insufficiency (unable to tolerate single lung ventilation and thoracotomy) or closed head injury. A total of 27% were managed non-operatively, and most demonstrated either resolution or improvement in the radiographical appearance of their injury. This article was presented at the 109th Southern Surgical Association in Hots Springs, Virginia, in 1997, which introduced me to bowling (in black tie, no less) and my mentor William Cioffi to his good friend and fellow golf enthusiast Martin Croce (figure 3).

## SECOND DECADE OF MEMPHIS CONTRIBUTIONS (2000–2010)

In the early phases of helical CT, image quality due to low scan resolution and a lack of familiarity and skill in image



**Figure 2** Representative CT images of blunt thoracic aortic injury. Images courtesy of Dr Timothy C Fabian.



**Figure 3** Drs Fabian, Davis, Croce, and Cioffi, 109th Annual Meeting of the Southern Surgical Association, Hot Springs, Virginia, 1998.

interpretation limited widespread enthusiasm and acceptance as a diagnostic modality. However, as technology rapidly improved, CT was commonly incorporated into diagnostic algorithms. The marked improvement in resolution allowed for the identification of small intimal injuries of unclear clinical significance. It was unclear whether all these injuries would require intervention or whether some would heal with aggressive medical management directed at aortic impulse control. In 2001, Dr Malhotra and colleagues reported on 87 BAI injuries during a 6-year period ending in 2000, of which nine patients were diagnosed with a minimal aortic injury.<sup>9</sup> Interestingly, five of these injuries were missed on conventional aortography but were confirmed as true injuries on intravascular ultrasound in four and videoangiography in the fifth. Of the nine patients, one patient underwent aortic repair; two died of associated injuries unrelated to their BAI; two injuries healed or remained stable; and two patients developed small pseudoaneurysms that did not require further intervention. The authors concluded that although the natural history of these minimal injuries was not completely known, non-operative management appeared to be a reasonable approach.

In 2000, the Eastern Association for the Surgery of Trauma (EAST) published Practice Management Guidelines (PMGs) on the diagnosis and management of BAIs. Although they acknowledged that there were no level I recommendations, three major level II recommendations were based on the work from Memphis and others: helical CT for diagnosis, medical management for aortic impulse control, and the use of centrifugal bypass for open repair.<sup>10</sup>

**Table 1** Grading of blunt thoracic aortic injury

Grade	Anatomic injury to the thoracic wall
I	Intimal tear
II	Mural thrombus/intramural hematoma
III	Pseudoaneurysm
IV	Rupture

Modified from Azizzadeh *et al.*<sup>13</sup>

**Table 2** Longitudinal study of BAI Dr. Fabian and colleagues

Authors	Study	Findings
Pate <i>et al</i> <sup>3</sup>	110 patients 88 patients managed with CPB	Paraplegia rates markedly improved with partial CPB, which augmented retrograde aortic perfusion.
Pate <i>et al</i> <sup>4</sup>	112 patients Anti-impulse therapy in 50 patients	Anti-impulse therapy was allowed for delayed repair with no in-hospital aortic rupture.
Gavatt <i>et al</i> <sup>6</sup>	21 patients underwent aortography and helical CT of the chest	Helical CT is effective for screening critically ill patients for BAI.
Minard <i>et al</i> <sup>5</sup>	34 patients Evaluated with TEE and aortography	Accuracy of TEE is similar to aortography and should not replace aortography as standard for diagnosis of BAI.
Fabian <i>et al</i> <sup>7</sup>	AAST prospective study ▶ 274 patients, 270 planned repair. ▶ CPB 65%.	Paraplegia rates significantly decreased with bypass techniques that provided distal aortic perfusion.
Fabian <i>et al</i> <sup>8</sup>	71 patients with BAI ▶ All had helical CT and aortography. ▶ All had anti-impulse therapy.	Helical CT is diagnostic and anti-impulse therapy eliminates in-hospital rupture.
Pate <i>et al</i> <sup>14</sup>	47 patients with BAI ▶ Helical CT for diagnosis. ▶ All had anti-impulse therapy. ▶ 11 patients did not require repair.	Selective management and delayed operative intervention for BAI are safe.
Nagy <i>et al</i> <sup>10</sup>	EAST PMGs	Helical CT is a useful screening modality, and delayed repair with anti-impulse therapy is safe in selected patients.
Malhotra <i>et al</i> <sup>9</sup>	87 patients with BAI and 9 with minimal injury (small intimal flap <1 cm, minimal hematoma)	Minimal aortic injuries heal spontaneously and may be managed non-operatively.
Santaniello <i>et al</i> <sup>15</sup>	84 patients with BAI and SOI	Non-operative management of SOI is safe despite heparinization for operative management BAI.
Fox <i>et al</i> <sup>12</sup>	EAST PMGs	Helical CT is diagnostic; endovascular repair is preferred; delayed repair is safe with anti-impulse therapy.
Fabian <sup>2</sup>	Roger T. Sherman Lecture, Southeastern Surgical Congress	Review of this history of the diagnosis and management of BAI

AAST, American Association for the Surgery of Trauma; BAI, blunt thoracic aortic injury; CPB, cardiopulmonary bypass; EAST, Eastern Association for the Surgery of Trauma; PMGs, Practice Management Guidelines; SOI, solid organ injury; TEE, transesophageal echocardiography.

## AND BEYOND

In the years that followed, technology permitted major advances in the repair of BAI, specifically the migration from open thoracotomy and graft placement for aortic repair to endovascular stent graft repairs. By 2007, there were 284 patients with BAI repaired with off-label stent grafts from 62 centers. The first Food and Drug Administration- approved thoracic stent graft, the Medtronic Valiant Stent Graft with the Captiva Delivery System, became available in 2012. In 2011, the Society for Vascular Surgery (SVS) released a clinical practice guideline with a weak recommendation in favor of endovascular stent grafting for repair of BAI.<sup>11</sup>

EAST revised its PMGs on the management of BAI in 2015, with Dr Fabian serving as the last author. In this article, they strongly recommended endovascular repair of BAI for those patients without a contraindication. They cited decreases in mortality and in paraplegia rates in support of these recommendations. In the same article, they acknowledged the work of Dr Fabian and others, acknowledging the safety of delayed aortic repair when medical therapy is used to reduce the risk of rupture while noting that those patients at highest risk of rupture (grade 3 and 4 injuries) were best served with urgent repair (table 1). The PMG acknowledged that the overall quality of evidence for delayed repair was variable, ranging from very low (stroke) to high (paraplegia), and thus suggested delayed repair in those patients who could effectively be managed medically and did not have the highest-grade aortic injuries.<sup>12 13</sup>

Current practice for BAI supports all the landmark paradigm practice changes originally proposed by Dr Fabian and colleagues. Helical CT scanning has effectively replaced aortography in the diagnosis of these injuries. Medical management, aimed at the control of aortic impulse to minimize rupture,

and the non-operative management of minimal injuries with serial imaging to assure stability versus improvement are now commonplace. Although aortic stent grafting has become the standard of care rather than open aortic replacement with circulatory support, the quality improvement efforts to reduce the devastating complications of paraplegia and in-hospital rupture harken back to the original musings of Dr Fabian and other thought leaders in the golden age of trauma surgery (table 2).

**Contributors** KAD is the sole author of this article.

**Funding** The authors have not declared a specific grant for this research from any funding agency in the public, commercial or not-for-profit sectors.

**Competing interests** None declared.

**Patient consent for publication** Not applicable.

**Ethics approval** Not applicable.

**Provenance and peer review** Commissioned; internally peer reviewed.

**Open access** This is an open access article distributed in accordance with the Creative Commons Attribution Non Commercial (CC BY-NC 4.0) license, which permits others to distribute, remix, adapt, build upon this work non-commercially, and license their derivative works on different terms, provided the original work is properly cited, appropriate credit is given, any changes made indicated, and the use is non-commercial. See: <http://creativecommons.org/licenses/by-nc/4.0/>.

## ORCID iD

Kimberly A Davis <http://orcid.org/0000-0001-5660-5293>

## REFERENCES

- 1 Parmley LF, Mattingly TW, Manion WC, Jahnke EJ. Nonpenetrating traumatic injury of the aorta. *Circulation* 1958;17:1086–101.
- 2 Fabian TC. Roger T. Sherman lecture. advances in the management of blunt thoracic aortic injury: parmley to the present. *Am Surg* 2009;75:273–8.
- 3 Pate JW, Fabian TC, Walker WA. Acute traumatic rupture of the aortic isthmus: repair with cardiopulmonary bypass. *Ann Thorac Surg* 1995;59:90–8;

- 4 Pate JW, Fabian TC, Walker WA. Traumatic rupture of the aortic isthmus: an emergency? *World J Surg* 1995;19:119–25;
- 5 Minard G, Schurr MJ, Croce MA, Gavant ML, Kudsk KA, Taylor MJ, Pritchard FE, Fabian TC. A prospective analysis of transesophageal echocardiography in the diagnosis of traumatic disruption of the aorta. *J Trauma* 1996;40:225–30.
- 6 Gavant ML, Menke PG, Fabian T, Flick PA, Graney MJ, Gold RE. Blunt traumatic aortic rupture: detection with helical CT of the chest. *Radiology* 1995;197:125–33.
- 7 Fabian TC, Richardson JD, Croce MA, Smith JS Jr, Rodman G Jr, Kearney PA, Flynn W, Ney AL, Cone JB, Luchette FA, et al. Prospective study of blunt aortic injury: multicenter trial of the American association for the surgery of trauma. *J Trauma* 1997;42:374–80;
- 8 Fabian TC, Davis KA, Gavant ML, Croce MA, Melton SM, Patton JH, Haan CK, Weiman DS, Pate JW. Prospective study of blunt aortic injury. *Annals of Surgery* 1998;227:666–77.
- 9 Malhotra AK, Fabian TC, Croce MA, Weiman DS, Gavant ML, Pate JW. Minimal aortic injury: a lesion associated with advancing diagnostic techniques. *J Trauma* 2001;51:1042–8.
- 10 Nagy K, Fabian T, Rodman G, Fulda G, Rodriguez A, Mirvis S. Guidelines for the diagnosis and management of blunt aortic injury: an East practice management guidelines work group. *J Trauma* 2000;48:1128–43.
- 11 Lee WA, Matsumura JS, Mitchell RS, Farber MA, Greenberg RK, Azizzadeh A, Murad MH, Fairman RM. Endovascular repair of traumatic thoracic aortic injury: clinical practice guidelines of the Society for vascular surgery. *J Vasc Surg* 2011;53:187–92.
- 12 Fox N, Schwartz D, Salazar JH. Evaluation and management of blunt traumatic aortic injury: A practice management guideline from the eastern association for the surgery of trauma. *J Trauma Acute Care Surg* 2014;78:136–45.
- 13 Azizzadeh A, Keyhani K, Miller CC, Coogan SM, Safi HJ, Estrera AL. Blunt traumatic aortic injury: initial experience with endovascular repair. *J Vasc Surg* 2009;49:1403–8.
- 14 Pate JW, Gavant ML, Weiman DS, Fabian TC. Traumatic rupture of the aortic isthmus: program of selective management. *World J Surg* 1999;23:59–63.
- 15 Santaniello JM, Miller PR, Croce MA, Bruce L, Bee TK, Malhotra AK, Fabian TC. Blunt aortic injury with concomitant intra-abdominal solid organ injury: treatment priorities revisited. *J Trauma* 2002;53:442–5.