

# The man, the myth, the method: an inside look at the open abdomen and abdominal wall reconstruction

Louis J Magnotti 

Surgery, The University of Arizona College of Medicine Tucson, Tucson, Arizona, USA

## Correspondence to

Dr Louis J Magnotti;  
ljmagnotti@yahoo.com

Received 15 February 2023

Accepted 8 March 2023

## ABSTRACT

Management of the open abdomen (or the abdomen that will not close) and subsequent abdominal wall reconstruction remains one of the most vexing situations for even the most experienced trauma surgeon. The contribution to the literature on this topic by Dr Timothy Fabian and the Memphis group at the Elvis Presley Trauma Center resulted in the contemporary recognition that the initial management as well as the long-term approach dictates optimal outcomes for patients with this problem. Over three decades, the Memphis group, under Dr Fabian's leadership, performed numerous clinical studies that led to the publication of multiple articles (including a step-by-step how-to manual) for managing the open abdomen from onset to closure. The purpose of this review is to survey the consecutive studies from Memphis specifically that led to the development of a simplified management scheme that has stood the test of time.

## FIRST IMPRESSIONS

The road from lifelong Yankee to becoming one of longest tenured staff at the Presley Regional Trauma Center in Memphis at the University of Tennessee Health Science Center is a story unto itself. What drew me to Memphis (besides the fact that they offered me a job) was the amazing faculty and their commitment to excellence in trauma patient care, research and education. On my first clinical day as a fellow, I walked up the hill from the Coleman Building (original site of surgical offices) to the trauma center with Dr Fabian and my cofellow. As we walked to the trauma center, Dr Fabian repeatedly referred to me as Luke—Catherine (my cofellow) implored me to correct him—when I refused to, she took it on herself to tell him my name was Lou (not Luke)—to which Dr Fabian merely grunted and walked away from us leaving us to Dr Croce. And so, my relationship with Dr Fabian had begun on a high note.

As a fellow, during teaching conferences, I often heard Dr Fabian refer to Northerners who had come to train in the South as hemorrhoids. This was apparently something he had been taught while he was in fellowship with Dr Harlan Stone. Accordingly, there were two types of Northerners—those who came down, trained and then went back up to the North to practice—this was a good hemorrhoid. In contrast, there were the unwanted hemorrhoids—those who came down to train and stayed and those who returned to the South after having been 'reduced'—I was the latter. However, it did not matter if you were from the North or the South,

student, resident, fellow or colleague—Dr Fabian loved to teach. In fact, I quickly learned that the easiest way to get Dr Fabian interested in a case was to make it sound as complex as possible—both the case as well as the proposed approach. There was nothing that Dr Fabian enjoyed more than a clinical challenge.

## EARLY FELLOWSHIP WORK

Not surprisingly, this (almost compulsive) attraction to only the most challenging clinical questions began early in his career. During fellowship with Dr Harlan Stone, he tackled a problem that continues to torment surgeons today—management of acute full-thickness losses of the abdominal wall.<sup>1</sup> The abdomen that will not close remains one of the most difficult situations for even the most experienced general surgeons to handle, especially one with inadequate native tissue to effect secure closure of the abdominal wall. It is here that Dr Fabian sought to begin to answer the best way to deal with this unwanted scenario (table 1).

During the 20-year study period, Stone and Fabian identified 167 patients with major abdominal wall defects. The majority were secondary to necrotizing soft tissue infection followed by destructive abdominal wall trauma. In their study, wound management and outcome varied. Without exception, primary closure of the abdominal wall (often under tension) resulted in wound infection and subsequent necrosis with an 85% mortality rate. The addition of a pedicled flap helped eliminate the tension yet a tenuous blood supply coupled with greater exposure of subcutaneous surface to significant polymicrobial contamination contributed to an unacceptably high rate of wound complications. For small defects (defined as <8 cm), gauze packing alone prevented evisceration and resulted in an acceptably low incidence of major wound complications. However, for those cases, with a sizable gap between abdominal side walls, insertion of a synthetic mesh to bridge the defect would serve to maintain abdominal domain. The same technique of gauze packing (described above) could then be used—but now it is placed directly on top of the mesh. Daily dressing changes continue until evisceration is no longer a concern and skin grafting is possible.

The principles gleaned from this initial early study (>40 years ago) would form the foundation for a simplified elegant management scheme (after some fine-tuning) for approaching the problem of the abdomen that will not close.

© Author(s) (or their employer(s)) 2023. Re-use permitted under CC BY-NC. No commercial re-use. See rights and permissions. Published by BMJ.

**To cite:** Magnotti LJ. *Trauma Surg Acute Care Open* 2023;**8**:e001111.

**Table 1** Selected studies of abdominal wall reconstruction by Fabian *et al*

| Authors                            | Study  | Findings   |
|------------------------------------|--|--|
| Stone <i>et al</i> <sup>1</sup>    | 167 patients with full-thickness abdominal wall defects.<br>► Managed with primary closure, pedicled flap closure or insertion of prosthetic with delayed coverage.  | Use of prosthetic (for any sizable defect) with delay in definitive reconstruction should be the preferred approach.   |
| Fabian <i>et al</i> <sup>2</sup>   | 88 patients managed during 8.5 years.<br>► Described and analyzed a defined management scheme for acute abdominal wall defects from the time of onset of the defect through the definitive reconstruction of the abdominal wall.   | For definitive reconstruction, a modification of the components separation technique should be used for moderate-sized midline defects.  |
| Jernigan <i>et al</i> <sup>3</sup> | 274 patients managed from onset of injury up to 60 months after injury.<br>► 73 had definitive abdominal wall reconstruction using the MCS technique.<br>► Mean follow-up was 24 months.<br>► Identified 4 recurrent hernias (5% rate).  | For definitive reconstruction, the MCS is the procedure of choice for repair of giant abdominal wall defects and should be accomplished within 6–12 months from initial hospital discharge.        |
| Bee <i>et al</i> <sup>4</sup>      | 51 patients with abbreviated laparotomy were randomized to receive either VAC or polyglactin 910 mesh for temporary abdominal closure at initial exploration to determine optimal technique.   | Both methods for abdominal coverage are equally likely to produce delayed primary fascial closure.   |
| DiCocco <i>et al</i> <sup>5</sup>  | 152 patients undergoing abdominal wall reconstruction during a 15-year period.<br>► 14 underwent delayed fascial closure±prosthetic, 47 underwent SCS±prosthetic and 91 underwent MCS±prosthetic.<br>► Long-term follow-up (up to 14.6 years) in 114 (75%) patients with a recurrence rate of 14% for all methods.<br>► Prosthetic use was associated with a fourfold increase in recurrence.<br>► 2 (5%) recurrences in MCS without prosthetic. | For definitive reconstruction, the modified components separation technique is the procedure of choice for repair of giant abdominal wall defects.   |
| DiCocco <i>et al</i> <sup>6</sup>  | Step-by-step technical approach to abdominal wall reconstruction, complete with diagrams, operative photos, pearls and pitfalls.   | The MCS—a modification of the components separation technique, developed at the Presley Memorial Trauma Center and shown to have one of the lowest recurrence rates in the literature—is detailed. |
| Lewis <i>et al</i> <sup>7</sup>    | 61 patients managed during 3 years with polyglactin 910 mesh followed by STSG.<br>► Determine optimal time to STSG by comparing early (<14 days) vs. late (≥14 days).  | For optimal results, STSG should be delayed at least 14 days after polyglactin 910 mesh placement.   |

MCS, modified components separation; SCS, standard components separation; STSG, Split Thickness Skin Graft; VAC, Vacuum-Assisted Closure.

## MEMPHIS EXPERIENCE

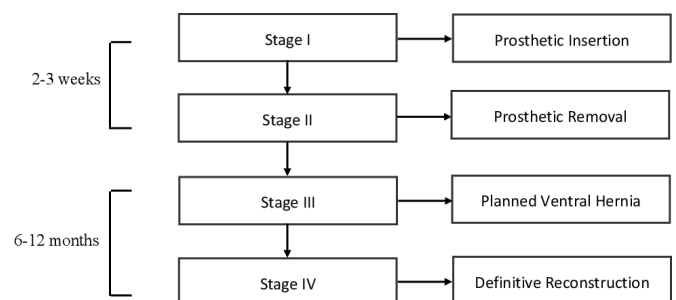
Not surprisingly, Dr Fabian took what he learned regarding the management of the open abdomen in Atlanta and brought it to Memphis. In 1994, Dr Fabian and his team published the equivalent of a how-to manual in the *Annals of Surgery*.<sup>2</sup> This study described and analyzed a management scheme for acute abdominal wall defects from the time of onset of the defect through the definitive reconstruction of the abdominal wall. Until this publication, a detailed description of the subsequent management of these wounds had not been available. In this study, the authors provide a comprehensive analysis of a staged management scheme for the initial and definitive treatment of acute abdominal wall defects.

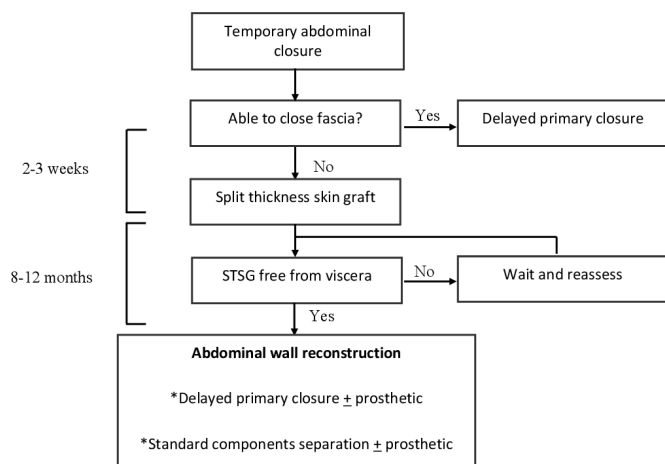
Eighty-eight cases managed during 8.5 years were analyzed—39 for visceral edema, 27 for abdominal sepsis and 22 for abdominal wall resection. In each case, the initial gap between the abdominal side walls was spanned by prosthetic—polypropylene mesh, polyglactin 910 mesh, polytetrafluorethylene mesh and plastic—stage I. As the edema resolves, the mesh is gradually pleated, allowing delayed fascial closure when possible. However, in patients without edema resolution, the absorbable mesh is removed 2–3 weeks after insertion to allow for granulation and fixation of the viscera with either split-thickness skin graft or full-thickness skin closure—stage II and formation of the planned ventral hernia—stage III. Definitive reconstruction occurs 6–12 months later (allowing for inflammation and dense adhesion resolution)—stage IV.

The authors provide a detailed step-by-step technique for each stage of the acute management of the abdominal wall defect and present their long-term findings—fistula rate of 9%, recurrent hernia rate by reconstruction technique (described below) and no wound-related mortality. In this study, Dr Fabian first describes his preferred technique of abdominal wall reconstruction—stage

IV—summarized nicely in a simple but elegant illustration (figure 4 of reference 2).

For definitive reconstruction, a modification of the components separation technique is introduced in this study and used for moderate-sized midline defects. In brief, the modification involves complete division of the anterior rectus sheath down to the arcuate line. The medial portion of the posterior rectus fascia is then sutured to the lateral portion of the anterior rectus fascia. This move will allow an additional 3–5 cm of further medial mobilization and provides excellent results when prior rectus abdominis resection has not been required—11% recurrent hernia rate. For larger defects (often involving resection of the rectus), the authors describe a prosthetic mesh repair—this has provided reasonably good abdominal wall integrity but at the cost of a significantly higher recurrent hernia rate—33%. Figure 1 depicts the author's four-staged approach and provides a simplified management scheme for treating acute abdominal wall defects.

**Figure 1** Four-staged approach to the management of acute abdominal wall defect.



**Figure 2** Refined three-staged approach to management of the open abdomen. STSG, Split Thickness Skin Graft.

### LESSONS FROM FELLOWSHIP

As stated above, Dr Fabian loved complex clinical problems and he loved to teach. As a fellow, one learned early on that the easiest way to capture and hold Dr Fabian's interest was to combine these two passions. In Memphis, the lab residents would help cover call on Friday and Saturday nights—this was how I met Wright Jernigan in 2001. Wright was working in the trauma lab at the time as well as on a clinical study looking at the acute and long-term results of Dr Fabian's staged management scheme for giant abdominal wall defects.<sup>3</sup> By this time, the management scheme (figure 2) had been further refined into three stages—absorbable mesh insertion (stage I), mesh removal with either skin grafting or full-thickness skin closure creating a planned ventral hernia (stage II) and definitive reconstruction (stage III).

In this study, 274 patients (35 with sepsis and 239 with hemorrhagic shock) with defects measuring on average 20×30 cm were studied—from onset of injury up to 60 months after injury. Of the 157 survivors, all underwent temporary closure with polyglactin 910 woven absorbable mesh. Delayed fascial closure was performed in 37 patients. Of the remaining 120 patients, there were 14 fistulae (8% of all survivors), no wound-related mortality and 73 had definitive abdominal wall reconstruction using the modified components separation technique. Mean follow-up was 24 months (range 2–60) with no postdischarge deaths. Most importantly, the authors identified only four recurrent hernias for a rate of 5%.

The authors once again present their consistent and effective staged approach for the management of the open abdomen. In the acute stage, absorbable mesh provides satisfactory coverage of the abdominal viscera with a low fistula rate. In those patients in which delayed fascial closure is not possible, coverage of the granulated wound as soon as the viscera is stuck (usually 14–21 days) reduces the fistula rate compared with longer periods of non-coverage of the granulating wound—this has been confirmed by subsequent work.<sup>4</sup> For definitive reconstruction, the modified components separation is the procedure of choice for repair of giant abdominal wall defects and should be accomplished within 6–12 months from initial hospital discharge.

Given Dr Fabian's seminal work on abdominal wall reconstruction<sup>2</sup> coupled with his above interests, I asked him one day, 'What do you think is the best way to reconstruct a planned ventral hernia?'—knowing that the trauma chief resident had booked one for later that week. He told me there was only one

way to do it and he would be glad to show me if I could find a case for him. Later that week, I performed my first (of many) abdominal wall reconstructions using Dr Fabian's modified components separation technique. Learning an operative technique from the surgeon who described it is an unbelievable experience. Although I had read all his articles in preparation for the operation, the subtle intricacies and operative tricks that were lost in the written word were effortlessly conveyed by Dr Fabian and spurred my interest in this elegant technique.

### JUMP-STARTING AN EARLY ACADEMIC CAREER

As with any academic career, it must begin somewhere. For me, I decided that the high volume at the Presley Regional Trauma Center would allow me to study some of the more controversial topics—those that generated varied opinions. One of the easiest ways to generate a research idea was to get Dr Fabian talking. It was during one of these casual conversations in Dr Croce's office that he suggested we should look at our abdominal wall reconstruction experience and ensure that we were providing optimal care for our patients with open abdomens. Then in 2009, twenty-nine years after his first article on abdominal wall defects—which had laid the foundation for his subsequent work on this subject—Dr Fabian once again presented at the annual meeting of the Southern Surgical Association—this time he shared lessons learned and how well his technique for abdominal wall reconstruction worked in a long-term follow-up study.

In this study,<sup>5</sup> 152 patients undergoing abdominal wall reconstruction during a 15-year period were identified. Fourteen patients underwent delayed fascial closure±prosthetic, 47 underwent standard components separation±prosthetic, and 91 underwent modified components separation±prosthetic. Long-term follow-up (up to 14.6 years, mean 5.3 years) was obtained in 114 (75%) of patients and demonstrated a recurrence rate of 14% for all methods—prosthetic use was associated with a four-fold increase in recurrence. The low recurrent hernia rate (5%) after modified components separation without prosthetics, with an excellent follow-up interval, provides good results for repair of major abdominal wall defects.

Once again, Dr Fabian had shown that for definitive reconstruction, the modified components separation technique is the procedure of choice for repair of giant abdominal wall defects. This approach can avoid the need for prosthetic material. The modified components separation without prosthetic resulted in an acceptably low hernia recurrence rate and should be used rather than prosthetic material. In the largest defects, adjunctive prosthetics may be necessary to avoid undue tension when all available autologous tissue has been maximally used—that is, after a modified components separation has been performed.

Finally, what better way to pay tribute to Dr Fabian and his technique than to write a technical 'how-to' article. In 2012, such an article was written—again with Dr Fabian leading the charge. The final product is a culmination of his vision on how his technique for abdominal wall reconstruction should be written, presented and disseminated. This article is a step-by-step technical approach to abdominal wall reconstruction, complete with diagrams, operative photos, pearls and pitfalls. In it, a modification of the components separation technique, developed in Memphis, Tennessee, at the Presley Memorial Trauma Center and shown to have one of the lowest recurrence rates in the literature, is described in detail—the modified components separation.

## LASTING INFLUENCE

Management of the open abdomen and the abdomen that will not close continues to generate varied and often heated opinions. It has been suggested (sometimes not so subtly) that Dr Fabian and the Memphis group somehow work to create open abdomens and fail to close ones that other institutions would routinely. Despite these unsubstantiated rumors, delayed fascial closure remains the goal in all patients managed initially with an open abdomen. Regardless, staged management of these wounds is at times unavoidable, and use of an absorbable mesh may be necessary (no matter how undesirable it may seem at first glance). Nevertheless, the use of this technique should remain the exception rather than the rule when managing open abdomens.

Fascial closure should be the goal for all patients. Various techniques to facilitate delayed primary fascial closure of the open abdomen have been proposed—judicious crystalloid use, application of abdominal wall tension with serial closure, sequential fascial closure starting at either end of the incision, use of a dynamic fascial closure system, and even early definitive closure with components separation. Although avoidance of an open abdomen with subsequent planned ventral hernia in trauma patients remains desirable, abdominal closure with prosthetic mesh after extensive loss of domain is sometimes unavoidable.



**Figure 3** The author (left) with Dr Timothy Fabian (right) at the 2002 Harwell Wilson Surgical Society Resident Graduation.

In the rare instance where, despite all efforts, one is faced with an abdomen that will not close, the technique described by Dr Fabian offers a simplified approach to help manage this difficult problem. Thus, 40 years later, the approach and management scheme proposed by him has stood the test of time and provides an out when nothing else will work.

As a former trauma/surgical critical care fellow, faculty member and partner to Dr Fabian in Memphis, I am grateful to have had the honor and privilege to be trained by and have worked with Dr Fabian. His thoughts, actions and teachings have helped shape the modern care of the trauma patient (figure 3).

**Contributors** LJM is the sole contributor to this article.

**Funding** The authors have not declared a specific grant for this research from any funding agency in the public, commercial or not-for-profit sectors.

**Competing interests** None declared.

**Patient consent for publication** Not applicable.

**Provenance and peer review** Commissioned; internally peer reviewed.

**Open access** This is an open access article distributed in accordance with the Creative Commons Attribution Non Commercial (CC BY-NC 4.0) license, which permits others to distribute, remix, adapt, build upon this work non-commercially, and license their derivative works on different terms, provided the original work is properly cited, appropriate credit is given, any changes made indicated, and the use is non-commercial. See: <http://creativecommons.org/licenses/by-nc/4.0/>.

### ORCID iD

Louis J Magnotti <http://orcid.org/0000-0002-3081-7594>

## REFERENCES

- 1 Stone HH, Fabian TC, Turkleson ML, Jurkiewicz MJ. Management of acute full-thickness losses of the abdominal wall. *Ann Surg* 1981;193:612–8.
- 2 Fabian TC, Croce MA, Pritchard FE, Minard G, Hickerson WL, Howell RL, Schurr MJ, Kudsk KA. Planned ventral hernia. staged management for acute abdominal wall defects. *Ann Surg* 1994;219:643–50;
- 3 Jernigan TW, Fabian TC, Croce MA, Moore N, Pritchard FE, Minard G, Bee TK. Staged management of giant abdominal wall defects: acute and long-term results. *Ann Surg* 2003;238:349–55;
- 4 Lewis RH, Sharpe JP, Croce MA, Fabian TC, Magnotti LJ. How soon is too soon?: optimal timing of split-thickness skin graft following polyglactin 910 mesh closure of the open abdomen. *J Trauma Acute Care Surg* 2020;89:377–81.
- 5 DiCocco JM, Magnotti LJ, Emmett KP, Zarzaur BL, Croce MA, Sharpe JP, Shahan CP, Jiao H, Goldberg SP, Fabian TC. Long-Term follow-up of abdominal wall reconstruction after planned ventral hernia: a 15-year experience. *J Am Coll Surg* 2010;210:686–95,
- 6 Bee TK, Croce MA, Magnotti LJ, Zarzaur BL, Maish GO, Minard G, Schroepel TJ, Fabian TC. Temporary abdominal closure techniques: a prospective randomized trial comparing polyglactin 910 mesh and vacuum-assisted closure. *J Trauma* 2008;65:337–42.
- 7 DiCocco JM, Fabian TC, Emmett KP, Magnotti LJ, Goldberg SP, Croce MA. Components separation for abdominal wall reconstruction: the Memphis modification. *Surgery* 2012;151:118–25.