

# Tracheoesophageal fistula repair in a sexagenarian in a persistent vegetative state: how palliative surgery ended in an awakening for both patient and physicians

Tyler M Bauer , Jonathan E Williams, Aasma Hossain, Gary Vercreusse

General Surgery, Michigan Medicine, Ann Arbor, Michigan, USA

## Correspondence to

Dr Tyler M Bauer; bauerty@med.umich.edu

## CASE PRESENTATION

A patient in their 60s initially presented to an outside hospital after a motor vehicle crash. Critically ill on arrival, the patient was noted to have multiple open long bone fractures, subdural and subarachnoid hematomas requiring intracranial ventricular monitoring, and a pelvic hematoma without active extravasation. The patient was intubated and sedated. The following day, the patient underwent exploratory laparotomy for hemorrhagic shock, resulting in a partial omentectomy and pelvic packing as well as a left above the knee amputation. The patient underwent multiple second look operations, and on hospital day 8, a gastric feeding tube placement and abdominal closure. On hospital day 17, the patient's abdominal wall was found to be dehissed, and pelvic hardware infected. The patient underwent tracheostomy complicated by an iatrogenic tracheoesophageal (TE) fistula ([figure 1](#)). The patient developed a rectovaginal fistula resulting

from pressure necrosis due to prolonged use of a fecal management system. By hospital day 40, the patient had minimal neurologic recovery and was unable to wean from the ventilator. There was a desire from the family to optimize the patient for a long-term acute care facility, and given the need for complex tracheoesophageal fistula (TEF) repair, the patient was transferred to our hospital for a second opinion.

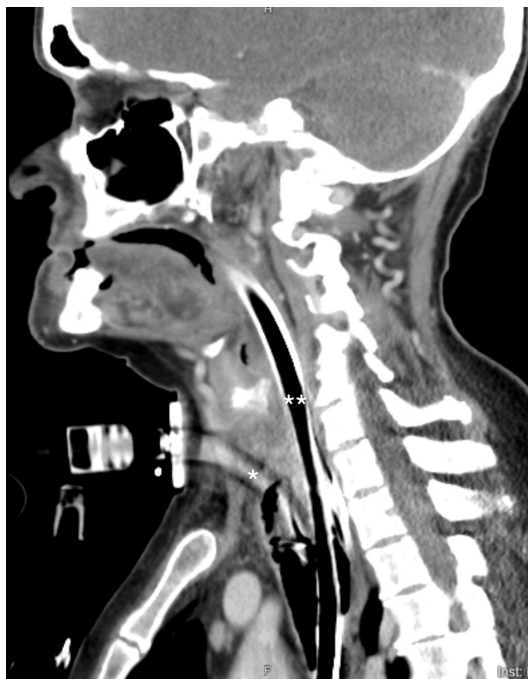On arrival, the patient was not on vasopressors, had been off antibiotics for 2 days, had only a mild leukocytosis and was otherwise stable. Neurologic critical care was consulted for neuroprognostication and felt that neurologic recovery would take months and meaningful neurologic recovery could not be guaranteed.

## WHAT WOULD YOU OFFER?

1. Primary repair of iatrogenic TE fistula.
2. Tracheal and esophageal stenting.
3. TE repair, colostomy, abdominal closure.
4. Colostomy and abdominal closure.
5. Comfort care.

## WHAT WE DID AND WHY

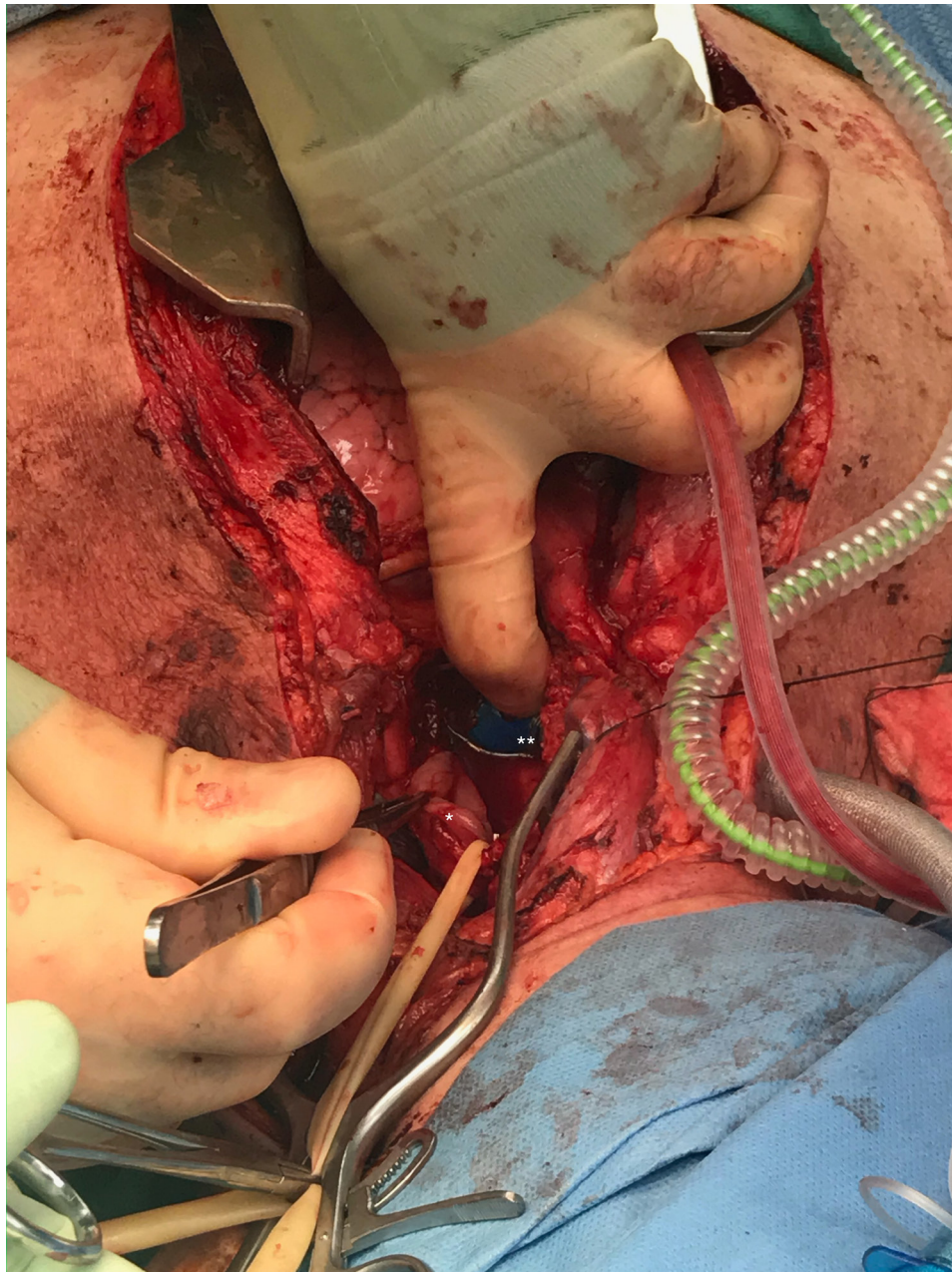
After discussing the patient's problems with family, they felt the patient would want continued aggressive care and an opportunity to recover, so we tailored the patient's care toward that goal rather than palliation. Given its proximal location, thoracic surgery felt that endoscopic stenting would be unsuccessful, and it was our impression that a TEF repair would be most likely to succeed with a traditional interposed muscle flap. The following day, the patient was taken to the operating room where an incision was carried over the anterior border of the left sternocleidomastoid (SCM) which was mobilized off its' cranial attachments in preparation for a rotational flap. Next, a median sternotomy was performed, and the left tracheoesophageal groove was exposed. The esophagus was encircled with a penrose drain, and a 5 cm defect in the anterior esophagus identified that communicated with the posterior trachea below the angle of Louis, with the endotracheal tube (ETT) visible through the tracheal defect ([figure 2](#)). The original tracheostomy tube was removed and after pre-oxygenating, the oral ETT was removed and an armored ETT placed through the tracheostomy tract directly into the trachea with the balloon at



**Figure 1** CT scan of patient's iatrogenic tracheoesophageal fistula on arrival. \*Marks tracheostomy that enters the esophagus. \*\*Marks the endotracheal tube that traverses the esophagus and enters the trachea.

© Author(s) (or their employer(s)) 2024. Re-use permitted under CC BY-NC. No commercial re-use. See rights and permissions. Published by BMJ.

**To cite:** Bauer TM, Williams JE, Hossain A, et al. *Trauma Surg Acute Care Open* 2024;**9**:e001296.



**Figure 2** Operative repair of the tracheoesophageal fistula through curvilinear incision along anterior border of the right sternocleidomastoid. \*Marks esophageal defect which is encircled with a penrose drain. \*\*Marks trachea with oral endotracheal tube distal to the tracheal defect.

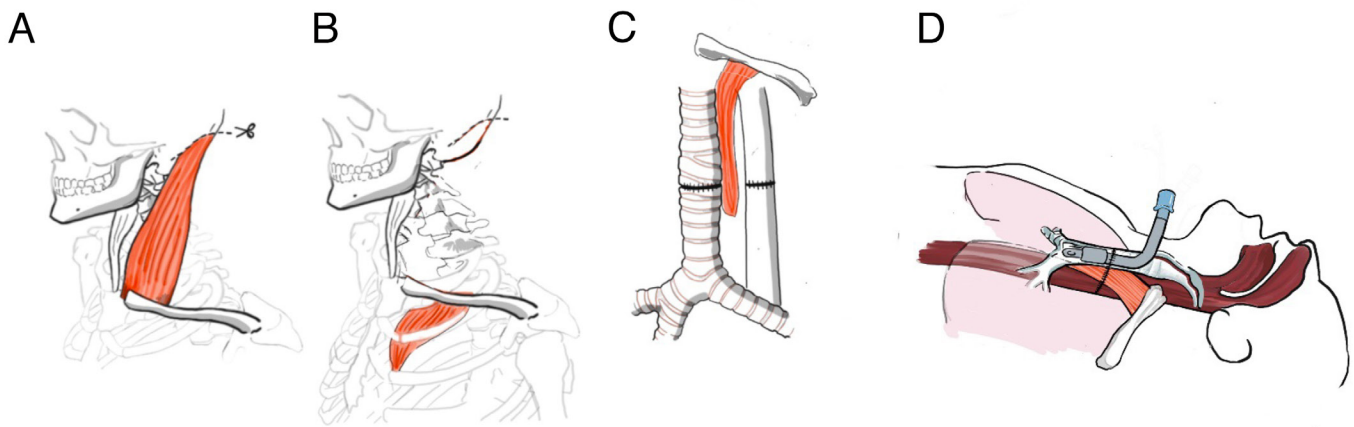
the carina. The esophageal injury was closed in two layers and the tracheal injury repaired. The SCM flap was rotated into the chest and placed between the esophageal and tracheal repairs. The distal nature of the injury did not facilitate tracheostomy placement at this time, therefore the armored ETT was left in place (figure 3).

Attention was then turned to the open abdomen, colovaginal fistula, and feeding. The patient had a cocoon abdomen and after a difficult dissection, the sigmoid colon was identified and brought out as a loop colostomy through the left rectus muscle. A Stamm gastrostomy tube was placed, and a right unilateral separation of components facilitated to allow for primary abdominal closure.

Over the next 3 weeks, the patient had esophagrams that were positive for a small esophageal leak, caudal to the TEF repair. This was managed conservatively, through conversion of G

tube to a GJ tube to reduce reflux. The patient had neurologic recovery over the next month, and communicated with staff by writing. A month after the patient's index operation, the ETT was converted to a tracheostomy and the patient was weaned off mechanical ventilation and discharged to an extended care facility. The patient was seen in our clinic twice after discharge and thereafter the patient's care was assumed by physicians closer to home. Approximately 10 months after discharge, the GJ tube was removed as the patient was tolerating a regular diet.

Although the situation seemed quite dire, this patient made a remarkable recovery. Contemporary literature predicts that half of all patients make meaningful and significant neurologic recovery when in a "persistent" vegetative state after trauma. In relatively healthy patients with clearly communicated wishes for all medical and surgical therapies after trauma, consideration for advanced and invasive medically indicated therapies in line



**Figure 3** Schematic of tracheoesophageal fistula (TEF) repair. (A) Dissecting the sternocleidomastoid (SCM) off of its cranial attachments. (B) Rotating the SCM into the mediastinum. (C) Buttressing the TEF repair with the SCM flap. (D) Oral endotracheal tube through old tracheostomy tract, with balloon distal to the TEF repair.

with patients values and wishes should occur, regardless of the complexity of the clinical scenario.

**Collaborators** None.

**Contributors** GV is the operative surgeon and TMB was the intensive care unit resident who cared for the patient. TMB, JEW and GV conceived the idea to submit the case as a case report and equally contributed to the text. AH was the medical illustrator and contributed to text as well. All authors discussed the results and contributed to the final manuscript.

**Funding** The authors have not declared a specific grant for this research from any funding agency in the public, commercial or not-for-profit sectors.

**Competing interests** None declared.

**Patient consent for publication** Not applicable.

**Ethics approval** This case report does not involve identifying information from the patient involved. The manuscript has been appropriately deidentified, and our institution does not require IRB approval for case reports. This case report does not involve identifying information from the patient involved. The manuscript has been appropriately deidentified.

**Provenance and peer review** Not commissioned; externally peer reviewed.

**Open access** This is an open access article distributed in accordance with the Creative Commons Attribution Non Commercial (CC BY-NC 4.0) license, which permits others to distribute, remix, adapt, build upon this work non-commercially, and license their derivative works on different terms, provided the original work is properly cited, appropriate credit is given, any changes made indicated, and the use is non-commercial. See: <http://creativecommons.org/licenses/by-nc/4.0/>.

**ORCID iD**

Tyler M Bauer <http://orcid.org/0000-0002-5430-5104>