


Large uterine fibroids causing a closed loop small bowel obstruction following uterine fibroid embolization

Amanda C Antono,¹ Julie Najjar,¹ Sunnie Y W Wong,² Justin Junn,¹
Lisa Marie Knowlton ^{3,4}

¹Department of Obstetrics and Gynecology, Stanford University School of Medicine, Stanford, California, USA

²Department of Surgery, Stanford University School of Medicine, Stanford, California, USA

³General Surgery, Stanford University, Stanford, California, USA

⁴Stanford University Medical Center, Palo Alto, California, USA

Correspondence to

Dr Lisa Marie Knowlton; drlmk@stanford.edu

Received 14 February 2024

Accepted 26 February 2024

CASE DESCRIPTION

A patient presented to the emergency department (ED) with abdominal pain and decreased oral intake for 1 day. Medical history was significant for uterine fibroids treated with uterine fibroid embolization (UFE) in 2021. CT of the abdomen and pelvis revealed a dilated loop of small bowel in the left hemiabdomen suspicious for small bowel obstruction (SBO) and an enlarged uterus containing multiple calcified fibroids with central necrosis. The patient had normal bowel function. Given the central necrosis of the fibroids, the pain was thought to be from a degenerating fibroid. The patient was discharged with acetaminophen, ibuprofen, and oxycodone.

One week later, the patient returned to the ED with abdominal pain, nausea, constipation, and obstipation for 3 days. CT demonstrated an SBO with a transition point in the right lower quadrant (RLQ) and a multifibroid uterus with an exophytic focus extending from the right fundus to the RLQ, adjacent to the transition point of the SBO. The patient underwent a trial medical management of SBO with bowel rest and decompression through a nasogastric tube. Pelvic MRI showed chronic ileus and delayed fecal transit likely secondary to mass effect from the large fibroid uterus with pelvic inflammation and peritonitis (*figure 1*).

Gastrografin challenge showed delayed transit of contrast reaching the descending colon. On hospital day 2, the patient was still clinically obstructed. The patient did not desire future fertility and had no prior abdominal operations.

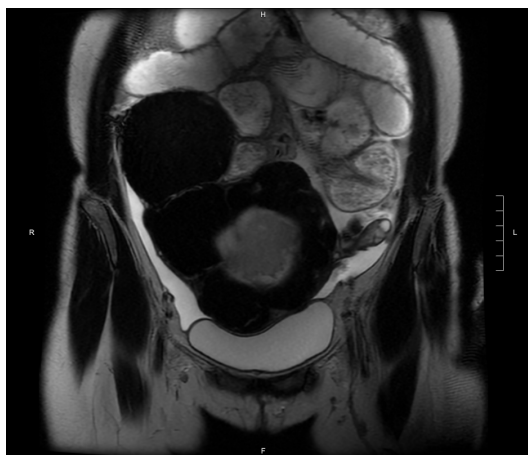

Figure 1 Pelvic MRI showing chronic ileus and delayed fecal transit likely secondary to mass effect from the large fibroid uterus with pelvic inflammation and peritonitis.

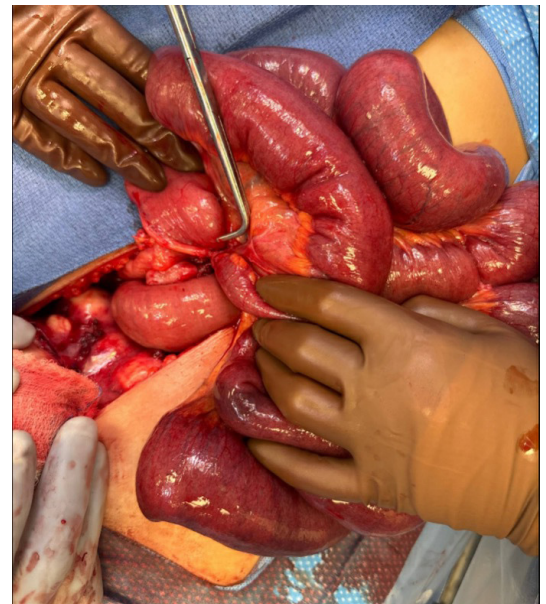

Figure 2 Adhesion causing closed loop small bowel obstruction.

WHAT WOULD YOU DO?

- Continue expectant management with bowel rest and nasogastric decompression.
- Repeat UFE.
- Take the patient to the operating room for myomectomy.
- Take the patient to the operating room for hysterectomy and possible small bowel lysis of adhesions.

WHAT WE DID AND WHY?

The clinical presentation was most consistent with either SBO from compression by the fibroid uterus versus an ileus from inflammation caused by surrounding uterine tissue necrosis. By hospital day 2, the patient was amenable to surgical intervention. We discussed treatment options including ongoing non-surgical management, versus surgical management via myomectomy or hysterectomy. Hysterectomy was recommended over myomectomy given that myomectomy alone could still predispose the patient to future issues with mass effect or inflammation, and since the patient did not desire future fertility. The patient elected for a hysterectomy as definitive management of uterine leiomyoma.

On hospital day 2, the patient underwent an exploratory laparotomy, total abdominal hysterectomy, and bilateral salpingectomy. We proceeded

© Author(s) (or their employer(s)) 2024. Re-use permitted under CC BY-NC. No commercial re-use. See rights and permissions. Published by BMJ.

To cite: Antono AC, Najjar J, Wong SYW, et al. *Trauma Surg Acute Care Open* 2024;**9**:e001425.

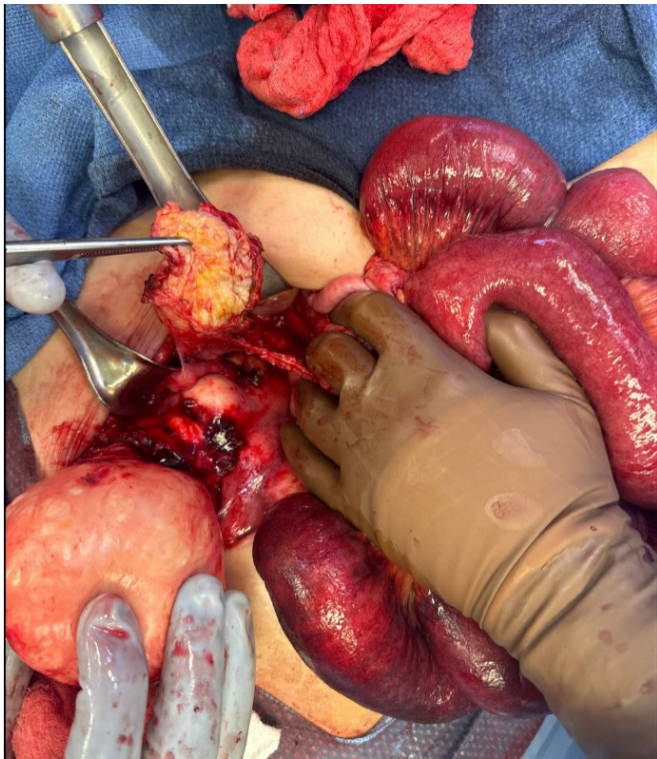

Figure 3 Right pelvic sidewall mass being excised.

with an open approach as the bulk and shape of the fibroid uterus limited pelvic domain, resulting in a limited xyphoid-to-umbilicus distance, and restricted any lateral uterine movement that would facilitate a laparoscopic hysterectomy.

Intraoperative findings were notable for a multifibroid uterus with primarily right-sided bulk nearly reaching the umbilicus, including a large pedunculated fibroid as well as adhesions to a mass in the right pelvic sidewall thought to be an old fibroid that had detached from the uterus over time. The general surgery team joined the gynecology team intraoperatively as multiple bowel adhesions and an appendiceal adhesion to the posterior uterus were also noted.

The patient underwent lysis of adhesions and appendectomy as the appendix was almost completely adhered to the posterior uterus. The small bowel was eviscerated and ran from the terminal ileum to the ligament of Treitz where an intra-loop adhesive band was found at the distal ileum causing a closed loop obstruction (figure 2). A portion of the jejunum appeared to be congested, although it had visible peristalsis that was thought to be from evisceration of the small bowel through the laparotomy which put tension on the mesentery. Congestion improved during

the course of the surgery. The patient underwent completion of the total abdominal hysterectomy and excision of the right pelvic sidewall mass without complications (figure 3). Cystoscopy was performed at the end of the case and showed bilateral ureteral jets without injury to the bladder. The patient had an uncomplicated postoperative course and was discharged on postoperative day 5. Pathology confirmed that the pelvic sidewall mass and the uterine fibroids were consistent with infarcted leiomyomata, as expected post-UFE.

Few case reports have described SBO after UFE or uterine artery embolization (UAE).¹⁻⁵ In two of these cases, an SBO resulted from an intraluminal obstruction from a fibroid through a uteroenteric fistula.^{4,5} Bowel was also noted to be adherent to the uterus, requiring a small bowel resection.^{4,5} In the above cases, the time frame to presentation of SBO ranged from 2 weeks to 11 years after UFE or UAE. Goldberg *et al*³ postulated that devascularization and ischemia after a UFE may cause inflammatory reactions in the fibroid and adjacent bowel leading to adhesion formation and subsequent bowel obstruction.

Contributors ACA: data collection and literature review, article writing. JN, SYWW: literature review, article revision. JJ: literature review, article critical revision. LMK: article critical revision, project supervision.

Funding The authors have not declared a specific grant for this research from any funding agency in the public, commercial or not-for-profit sectors.

Competing interests None declared.

Patient consent for publication Not required.

Provenance and peer review Not commissioned; internally peer reviewed.

Open access This is an open access article distributed in accordance with the Creative Commons Attribution Non Commercial (CC BY-NC 4.0) license, which permits others to distribute, remix, adapt, build upon this work non-commercially, and license their derivative works on different terms, provided the original work is properly cited, appropriate credit is given, any changes made indicated, and the use is non-commercial. See: <http://creativecommons.org/licenses/by-nc/4.0/>.

ORCID iD

Lisa Marie Knowlton <http://orcid.org/0000-0001-6046-5035>

REFERENCES

- Hames K, Athreya S. Rare instance of small bowel obstruction following unilateral uterine artery Embolization. *J Vasc Interv Radiol* 2013;24:S1051-0443(13)01051-8:1417-9..
- Payne JF, Haney AF. Serious complications of uterine artery Embolization for conservative treatment of Fibroids. *Fertil Steril* 2003;79:128-31.
- Goldberg J, Boyle K, Choi M, Panchal N. Small bowel obstruction due to adhesive disease observed after uterine Fibroid Embolization. *Am J Obstet Gynecol* 2005;193:892-3.
- Roberson JL, Krumeich LN, Darwich NF, Babatunde V, Laczko D, Albee A, Yang Z, Jack AE, Shlansky-Goldberg R, DeAgostino-Kelly M, *et al*. Fibroid expulsion: a unique presentation of mechanical small bowel obstruction 11 years after uterine artery Embolization: a case report. *J Med Case Rep* 2021;15:356.
- Virmani V, Fasih N, Rakhra K. Intraluminal bowel obstruction by a detached Fibroid- an extremely unusual complication of uterine artery Embolization. *Clin Radiol* 2011;66:795-7.