

# Updates in traumatic brain injury management: brain oxygenation, middle meningeal artery embolization and new protocols

Tanya Egodage <sup>1</sup>, Purvi Pravinchandra Patel <sup>2,3</sup>

<sup>1</sup>Surgery, Cooper University Health Care, Camden, New Jersey, USA

<sup>2</sup>Department of Surgery, Loyola University Chicago, Maywood, Illinois, USA

<sup>3</sup>Department of Surgery, Loyola University Medical Center, Maywood, Illinois, USA

## Correspondence to

Dr. Tanya Egodage; egodage-tanya@cooperhealth.edu

Received 15 January 2024

Accepted 5 March 2024

## SUMMARY

Traumatic brain injury (TBI) confers significant morbidity and mortality, and is a pathology often encountered by trauma surgeons. Several recent trials have evaluated management protocols of patients with severe TBI. The Brain Oxygen Optimization in Severe Traumatic Brain Injury Phase-II trial (BOOST-II) evaluated efficacy and feasibility of brain oxygen measurement in severe TBI. BOOST phase 3 trial (BOOST-3) and two ongoing trials look to measure functional outcomes in this population. Furthermore, middle meningeal artery embolization has now become standard therapy for adult patients with chronic subdural hematoma (SDH) and has increasing popularity in those with recurrent SDH as an alternative to surgical intervention. In this manuscript, we review the literature, ongoing trials, and discuss current updates in the management of TBI.

## INTRODUCTION

Traumatic brain injury (TBI) confers a significant healthcare burden, reported to result in 190 deaths per day in the USA, disabling far more, and accruing billions of dollars in healthcare expenditures per year.<sup>1</sup> Trauma surgeons treat patients with TBI and its sequelae, daily. Understanding the pathophysiology, and current research and recommendations are vital to improving care for this vast population of patients.

Brain injury includes both primary injury and secondary injury. Primary injury denotes the initial insult that occurs immediately following trauma. Secondary injury evolves over the subsequent hours to days and occurs due to altered cerebral metabolism, cerebral blood flow and arterial oxygen content.<sup>2</sup> Current medical therapies include efforts to improve hemodynamics by altering blood pressure and intracranial volumes are meant to optimize cerebral perfusion pressure (CPP) and intracranial pressure (ICP). However, ICP alterations occur due to a variety of pathologies, including mass effect, edema, cerebrospinal fluid disturbances and venous outflow obstruction. As such, it is an indiscriminate marker of the truly desired endpoints of cerebral perfusion and oxygenation. Although measurement of ICP in patients with moderate to severe TBI is helpful, ICP elevations may be a late indicator of deterioration, are non-specific and may limit time for intervention and prevention of further injury.<sup>3</sup> Authors continue to investigate methods to enhance brain perfusion and oxygenation in efforts to improve outcomes for patients with TBI.

Furthermore, the use of middle meningeal artery embolization (MMAE) has increased in popularity for the treatment of chronic and recurrent subdural hematoma (SDH). Historical management of chronic SDH (cSDH) included surgical intervention, but this interventional technique affords resolution with an acceptable complication rate. In this manuscript, we review the updates in TBI management, including brain oxygenation, MMAE and newly recommended protocols.

## BRAIN OXYGENATION

Hypoxia is known to be independently associated with mortality in patients with TBI, with multiple studies demonstrating a dose-dependent increase in mortality with worsening hypoxia.<sup>4-6</sup> Several mechanisms have been proposed to increase oxygen delivery, including the use of transfusions and vasoactive agents, jugular venous oxygen measurement and brain tissue oxygen measurement.

Given the known correlation between hypoxic events and mortality in TBI, researchers have proposed direct measurement of partial pressure of oxygen in brain tissue PbtO<sub>2</sub> as a means to improve outcomes.<sup>5 7-9</sup> Direct brain oxygen measurements are conducted via intracranial probes capable of oxygen detection placed via craniotomy. Prior reports note unfavorable outcomes when PbtO<sub>2</sub> measures less than 15 mm Hg in the setting of ICP >20 mm Hg.<sup>5 10 11</sup> Observational trials including patients with TBI demonstrate that a majority of patients ultimately fall below 20 mm Hg at some point during their intensive care unit (ICU) course.<sup>7</sup> Chang *et al* further elicited that hypoxia is common in patients with severe TBI and is independent of ICP elevation.<sup>7 11</sup> Whether PbtO<sub>2</sub> measurement is a better predictor of TBI-related ischemia remains to be determined. Furthermore, the ideal location of the PbtO<sub>2</sub> probe placement, namely, whether within the injured brain tissue, adjacent to the area of injury or remote from the injury, is currently unknown.

The American College of Surgeons Trauma Quality Improvement Guidelines Best Practices in the Management of TBI recommend the assessment of cerebral autoregulation. Specifically, cerebrovascular pressure reactivity index, cerebral blood flow evaluation and transcranial Doppler monitoring may determine whether a patient has preserved cerebral autoregulation. This determines ICP and CPP goals. In patients with poor cerebral autoregulation, advanced techniques such as evaluation of

© Author(s) (or their employer(s)) 2024. Re-use permitted under CC BY-NC. No commercial re-use. See rights and permissions. Published by BMJ.

**To cite:** Egodage T, Patel PP. *Trauma Surg Acute Care Open* 2024;**9**:e001382.

**Table 1** BOOST-II interventions as classified by tier

Tier 1	Tier 2	Tier 3
Head of bed elevation	CO <sub>2</sub> and O <sub>2</sub> optimization	Pentobarbital coma
Sedation, analgesics and antiepileptics	Neuromuscular blockade	Cardiac inotropes
CSF drainage	Surgical treatment of lesions	Decompressive craniectomy
Target temperature <38°C	Target 36°C	Target 32–35°C for salvage
CPP optimization	Hyperosmolar therapy	
	Cerebral autoregulation	
	Transfuse PRBC	

BOOST-II, Brain Oxygen Optimization in Severe Traumatic Brain Injury Phase-II trial; CO<sub>2</sub>, carbon dioxide; CPP, cerebral perfusion pressure; CSF, cerebrospinal fluid; PaO<sub>2</sub>, partial pressure of oxygen; PRBC, packed red blood cells.

brain tissue oxygen and jugular venous oxygen saturation may be utilized.<sup>8</sup>

The Brain Oxygen Optimization in Severe Traumatic Brain Injury phase-II trial (BOOST-II) aimed to evaluate the effects of brain oxygen measurement and treatment on TBI patient outcomes.<sup>9</sup> Patients with a severe TBI identified as Glasgow Coma Score (GCS) of 8 or less or those with a greater GCS who rapidly declined after admission were selected for enrollment. All patients had both an ICP and PbtO<sub>2</sub> monitors placed. Patients were subsequently randomized into two groups to determine the triggers for tiered therapeutic interventions: ICP only versus the ICP+PbtO<sub>2</sub> group. For the ICP only group, tiered interventions were provided if ICP was ≥20 mm Hg for 5 min and recordings from the PbtO<sub>2</sub> monitors remained blinded during the study period. The ICP+PbtO<sub>2</sub> group was given interventions for either ICP 20 mm Hg or PbtO<sub>2</sub> ≤20 mm Hg lasting greater than 5 min. **Table 1** delineates some of the recommended BOOST-II interventions based on tier.

A total of 119 patients were enrolled, of which 106 had 6-month follow-up data. The ICP+PbtO<sub>2</sub> group had less time with brain hypoxemia and when hypoxic events did occur, the average depth of hypoxemia was less compared with the ICP only group. These results are all statistically significant and delineated in **table 2**. ICP remained similar between the two groups, validating that cerebral hypoxia is independent of ICP.<sup>9</sup>

The secondary outcomes of safety and feasibility were achieved. PbtO<sub>2</sub> measurement and titration were safe without any significant serious adverse events. The study demonstrated good compliance with a complex management algorithm with minimal protocol violations. Overall, Glasgow Outcome Scale-Extended (GOS-E) and Disability Rating Scale (DRS) were evaluated as long-term outcomes at 6 months, and were similar between groups, although there was a trend towards improved outcomes and lower mortality among the PbtO<sub>2</sub> group. **Tables 3 and 4** demonstrate these results (**tables 3 and 4**).<sup>9</sup> Overall, fewer patients were noted to have worse disability scores in the

**Table 2** Results of BOOST-II trial

PbtO <sub>2</sub> metric	Result
Proportion of time below 20 mm Hg	Greater for ICP vs PbtO <sub>2</sub> +ICP group
Average depth (mm Hg)	Greater for ICP vs PbtO <sub>2</sub> +ICP group
Area over the curve (mm Hg x hr)	Greater for ICP vs PbtO <sub>2</sub> +ICP group

BOOST-II, Brain Oxygen Optimization in Severe Traumatic Brain Injury Phase-II trial; ICP, intracranial pressure; PbtO<sub>2</sub>, partial pressure of brain tissue oxygen; vs, versus.

**Table 3** BOOST-II Glasgow Outcome Scale—Extended at 6 months by treatment group

GOS-E	PbtO <sub>2</sub> +ICP	ICP only
8	13%	6%
7	11%	8%
6	9%	9%
5	8%	8%
4	19%	23%
3	13%	9%
2	2%	4%
1	25%	34%

BOOST-II, Brain Oxygen Optimization in Severe Traumatic Brain Injury Phase-II trial; GOS-E, Glasgow Outcome Scale—Extended; ICP, intracranial pressure; PbtO<sub>2</sub>, partial pressure of brain tissue oxygen.

PbtO<sub>2</sub>+ICP group over those managed with ICP treatments alone. This phase II trial was terminated early given positive results.

Whereas BOOST-II evaluated the feasibility and efficacy of a complex treatment protocol, current trials are evaluating whether additional PbtO<sub>2</sub> monitoring results in improved outcomes, the Intracranial Pressure Monitoring with and without Brain Tissue Oxygen Pressure Monitoring for Severe Traumatic Brain Injury in France (OXY-TC) studied the superiority of ICP with PbtO<sub>2</sub> measurement over ICP monitoring alone. Patients aged 18–75 years old with severe blunt TBI were assigned to either ICP only or ICP+PbtO<sub>2</sub> arms. Three hundred eighteen patients were included over 5 years. The primary outcome was Glasgow Outcome Scale-Extended (GOSE) at 6 months, with similar ICP and PbtO<sub>2</sub> parameters to BOOST-II. Researchers determined that ICP+PbtO<sub>2</sub> did not improve GOSE as compared with ICP alone. There was a significantly increased incidence of intracerebral hematoma with the PbtO<sub>2</sub> group, and no difference in mortality at 12 months.<sup>12</sup>

Two additional ongoing trials attempt to corroborate or refute these findings. BOOST phase 3 (BOOST-3) trial is investigating functional outcomes for patients with severe blunt TBI with ICP only or ICP+PbtO<sub>2</sub>. This trial, open in the USA and Canada, is currently enrolling patients ≥14 years of age, who present after blunt injury with CT-confirmed TBI and depressed GCS. All patients receive both ICP and PbtO<sub>2</sub> catheters. Physicians select treatment from a tiered algorithm. Functional and behavioral outcomes will be assessed via the GOSE at 6 months.

The Brain Oxygen Neuromonitoring in Australia and New Zealand—Global Trial (BONANZA) is being conducted in a similar fashion to BOOST-3. Patients ≥17 years old, with severe blunt TBI and a GCS <9 will be stratified into ICP monitoring only or ICP+PbtO<sub>2</sub>. Similar to both BOOST-3 and OXY-TC, the primary outcome is GOSE at 6 months. Given the similarities between study designs of the three aforementioned trials,

**Table 4** BOOST-II Disability Rating Scale at 6 months

DRS	PbtO <sub>2</sub> +ICP	ICP only
0	21%	13%
1–11	45%	45%
12–29	9%	8%
Died	25%	34%

BOOST-II, Brain Oxygen Optimization in Severe Traumatic Brain Injury Phase-II trial; DRS, Disability Rating Scale; ICP, intracranial pressure; PbtO<sub>2</sub>, partial pressure of brain tissue oxygen.

future meta-analysis is anticipated. Results from BOOST-3 and BONANZA are pending and will assist in guiding monitoring and subsequent interventions for patients with severe TBI in the future.<sup>13</sup>

As we await results from these ongoing trials, current guidelines per the Brain Trauma Foundation (BTF), state that PbtO2 measurements should be utilized to monitor oxygen delivery only if hyperventilation is used.<sup>14</sup> However, at the 2022 meeting of The Seattle International Severe Traumatic Brain Injury Consensus Conference (SIBICC), international experts developed an algorithm to integrate ICP and PbtO2 measurement in treatment.<sup>15</sup> This algorithm is described below in the New protocols section of this manuscript. Additional measures of brain oxygenation and perfusion including arterio-jugular venous oxygen measurements, cerebral microdialysis and transcranial Doppler examination are areas of ongoing research in patients with TBI.

### MIDDLE MENINGEAL ARTERY EMBOLIZATION

The MMA has long been implicated as an associated vessel in patients who sustain epidural hematomas. As it perfuses the dura, the MMA has also been associated with the development and progression of chronic SDHs (cSDH). Given the shortcomings of surgical treatment of cSDH, MMAE has emerged as an alternate technique for treatment of this insidious problem.

Although the exact mechanism remains unclear, cSDH is thought to develop secondary to the chronic inflammation following an acute SDH. Recurrence of an SDH is reported in up to 37% of patients, even after surgical evacuation.<sup>16</sup> Studies have demonstrated a small vessel communication between the MMA and vessels on the outer membrane of the cSDH. As such, MMAE has been proposed as a technique for treatment of cSDH.

MMAE was initially described in a publication by Mandai *et al* in conjunction with burr hole craniotomy for a patient with a cSDH.<sup>17</sup> The patient had improvement of neurologic function and no permanent deficits. Given the positive results of this case report, it became increasingly studied. Okuma's research group evaluated 17 patients receiving MMAE for refractory cSDH. No patients had recurrence or complications following embolization. This early report demonstrated the efficacy of MMAE therapy.<sup>18</sup>

Additional trials have evaluated the efficacy of MMAE in cSDH as a primary treatment strategy or following recurrence after other interventions. Multiple case series utilizing MMAE as a primary therapy for cSDH have demonstrated between 50% and 88% reduction in cSDH on repeat imaging, with none of the treated patients demonstrating recurrence on 6-month follow-up.<sup>19–22</sup> Shotar *et al* found that patients who received MMAE for risk of cSDH recurrence had significantly fewer recurrences.<sup>23</sup> Ng *et al*, found that patients receiving surgery with MMAE for cSDH had greater hematoma resolution as compared with surgery alone. No endovascular-related complications were noted.<sup>24</sup> There is additional evidence to demonstrate that MMAE is superior to conventional surgery as well.<sup>25</sup>

A systematic review of the literature published by Di Cristofori *et al* evaluated risks and benefits of MMAE and found that the procedure is safe with very few documented complications and a low failure rate. MMAE can be used as an adjunct to surgery or as an isolated treatment for cSDH.<sup>26</sup> An additional study found that patients treated with MMAE have no difference in mortality, outcomes or the need for surgical rescue as opposed to primary surgery and may be an optimal option in patients with high Charlson comorbidity indices.<sup>27</sup> Given this breadth of

literature, MMAE has now become a standard therapy for adult patients with cSDH.

As any intervention, MMAE is not without failure. Salem *et al* retrospectively evaluated clinical failure of 530 patients who underwent 636 MMAE over 3 years at 13 centers in the USA. Clinical failure, defined as neurologic deterioration requiring surgical intervention, or hematoma accumulation, occurred in 36 (6.8%) patients. Predictors of failure included pretreatment anticoagulation therapy, MMA diameter <1.5 mm. Non-failure was associated with liquid embolic agents. On the other hand, radiographic failure, defined as hematoma reduction <50%, was identified in 137 (26.3%) patients. Radiologic failure occurred in those with MMA diameter <1.5 mm, presence of a midline shift, and superselective MMA catheterization, whereas non-failure occurred in female sex, those with concurrent surgical evacuation, and a longer imaging follow-up time.<sup>28</sup>

Pediatric patients have a lesser incidence of cSDH given its etiology, however, studies demonstrate the efficacy of MMAE in this population as well.<sup>29</sup> Further research is required to validate these findings but MMAE appears to be a promising option.

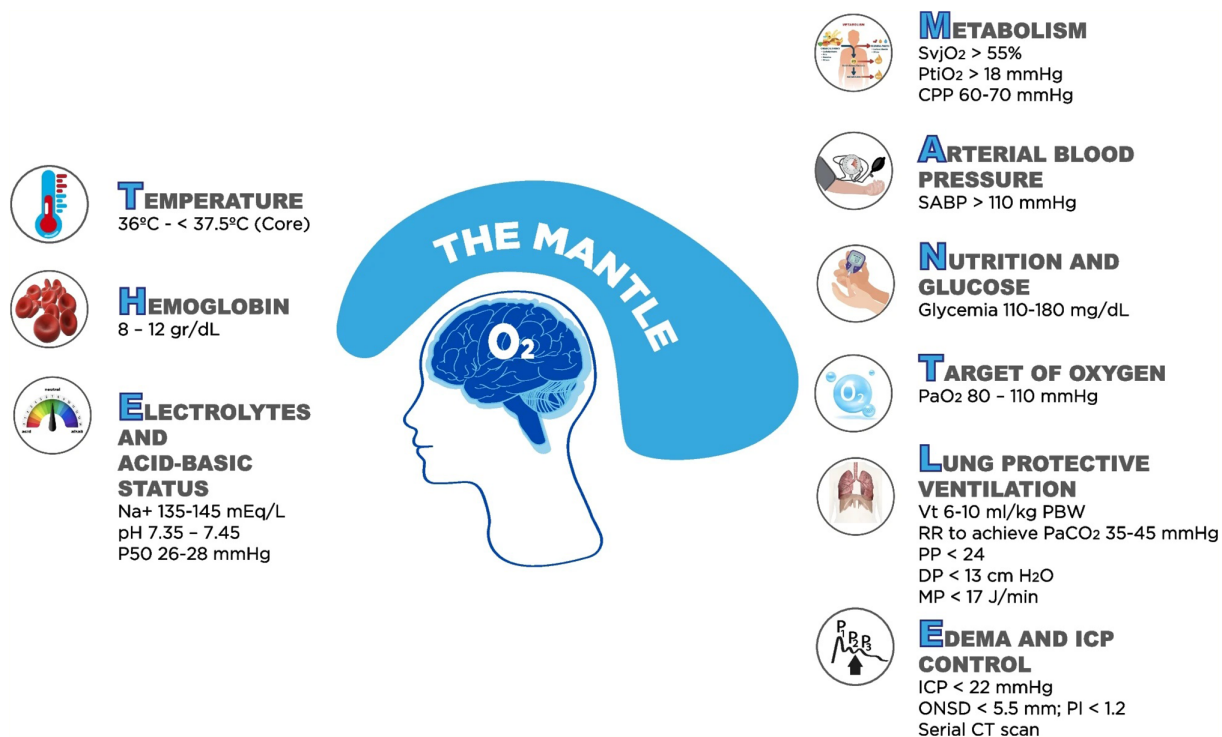
Overall, MMAE is associated with acceptable resolution and complication rates and serves as an optimal management technique for selected patients.

### NEW PROTOCOLS

Over the last decade, new protocols have been established in the management of TBI. Several national organizations have published updated recommendations on the care of patients with TBI, commensurate with updated literature. One such organization, the BTF, who publish guidelines for the management of mild, moderate and severe TBI, has incorporated evidence for improvement of care in the prehospital setting. Recent literature notes worsened outcomes in patients with TBI sustaining hypoxia or hypotension and worsened outcomes when these occur independently. Noting the need for prevention of hypoxia and hypotension, although brief, in the field, there is a stronger recommendation to maintain arterial oxygen saturation and hemodynamic parameters. BTF now recommends maintenance of systolic blood pressure above 110 mm Hg, given that lower pressures have been associated with worsened outcomes. Likewise, oxygen saturation should be maintained above 90%. In fact, patients with suspected TBI are now recommended to be placed on supplemental oxygen to minimize the potential for hypoxic events. Blood pressures should be measured every 5–10 min in the prehospital setting with appropriately sized cuffs. Pediatric age-appropriate blood pressures should be maintained (table 5). In the austere environment, signs of end-organ perfusion, including capillary refill time, neurologic status and quality of peripheral pulses, should be utilized for pediatric patients. Furthermore, ventilation should be monitored and maintained between 35 and 45 mm Hg in those with altered consciousness.

**Table 5** Age-appropriate pediatric blood pressure targets for pre-hospital management of TBI

Age	Blood pressure recommendation
28 days and younger	>70 mm Hg
1–12 months	>84 mm Hg
1–5 years	>90 mm Hg
6 years and older	>100 mm Hg
Adults	110 mm Hg and above
TBI, traumatic brain injury.	



**Figure 1** THE MANTLE recommendations for optimization of cerebral oxygenation. Adopted from Godoy DA, *et al.*<sup>2</sup> SvjO<sub>2</sub>, venous jugular oxygen content; PtiO<sub>2</sub>, partial pressure of brain tissue oxygen; CPP, cerebral perfusion pressure; SABP, systolic arterial blood pressure; PaO<sub>2</sub>, arterial partial pressure of oxygen; Vt, tidal volume; RR, respiratory rate; PP, plateau pressure; DP, driving pressure; PI, pulsatility index; MP, mechanical power; ICP, intracranial pressure; ONSD, optic nerve sheath diameter; CT, computed tomography.

Attention to temperature was also noted, with maintenance of euthermy (36°C–37°C).<sup>30</sup>

Recommendations for GCS evaluation include that standard GCS should be utilized for children over 2 years of age, and pediatric scoring utilized below this age cut-off. GCS should be reported every 30 min in the field, and changes in status reported to the receiving institution. In resource-limited settings, providers may use the motor score for both adult and pediatric patients. The need for improved prehospital documentation was noted in this recommendation.

BTF also recommends that patients with suspected TBI should be transported to facilities with the ability to obtain CT and with neurosurgical capabilities.

The SIBICC specifically offers guidance on management of severe TBI. Given ongoing data surrounding PbtO<sub>2</sub> evaluation, the SIBICC developed protocols based on Delphi-method consensus to guide therapy. They recommend a tiered approach to optimize ICP, cerebral perfusion and oxygenation. Tier 0 treatment involves a neuroprotective strategy to prevent further decline, regardless of ICP measurement. Tiers 1–4 stratify patients based on PbtO<sub>2</sub> and use sedation and analgesics, ventilator compliance, temperature management and CPP management to optimize cerebral perfusion and oxygenation and prevent ischemic events.<sup>31</sup>

Godoy and colleagues developed a bundle to be used in the ICU for management of patients with TBI (figure 1). This approach includes evaluation and management of metabolic parameters, arterial blood pressure, nutrition and glucose, oxygenation, lung protective ventilation, control of edema and ICP, temperature, hemoglobin and electrolytes.<sup>2</sup> The constellation of these has been summarized as the abbreviation ‘THE MANTLE.’ Whether this protocol improves outcomes globally will require further investigation, but it may increase the ability

for multidisciplinary teams to communicate and streamline care for patients with severe TBI.

## CONCLUSIONS

The management of TBI continues to evolve. Brain tissue oxygen measurement offers promise in guiding therapies and preventing cerebral ischemia in conjunction with ICP management for patients with severe TBI. MMAE is increasingly becoming standard therapy for chronic and recurrent SDHs. Finally, new treatment algorithms incorporating these advances have been proposed to optimize prehospital and in-hospital care of patients with TBI. Trauma surgeons should continue to investigate mechanisms to improve both short-term and long-term functional outcomes for this considerable patient population.

✉ Tanya Egodage @DrTanyaEgodage

**Contributors** TE and PPP made substantial contributions to the design of the article. Literature review completed by TE and PPP. TE drafted the article, with critical revisions provided by PPP. Both TE and PPP approved for this version of the manuscript to be published and agreed to be accountable for all aspects of the work in ensuring that questions related to the accuracy or integrity of any part of the work were appropriately investigated and resolved.

**Funding** The authors have not declared a specific grant for this research from any funding agency in the public, commercial or not-for-profit sectors.

**Competing interests** None declared.

**Patient consent for publication** Not applicable.

**Ethics approval** Not applicable.

**Provenance and peer review** Not commissioned; internally peer-reviewed.

**Open access** This is an open access article distributed in accordance with the Creative Commons Attribution Non Commercial (CC BY-NC 4.0) license, which permits others to distribute, remix, adapt, build upon this work non-commercially, and license their derivative works on different terms, provided the original work is

properly cited, appropriate credit is given, any changes made indicated, and the use is non-commercial. See: <http://creativecommons.org/licenses/by-nc/4.0/>.

#### ORCID iDs

Tanya Egodage <http://orcid.org/0000-0002-7386-2926>

Purvi Pravinchandra Patel <http://orcid.org/0000-0001-6935-6572>

#### REFERENCES

- Centers for Disease Control and Prevention. Web-based injury Statistics query and reporting system. 10 August 2023. Available: <https://www.cdc.gov/injury/wisqars/fatal/trends.html>
- Godoy DA, Murillo-Cabezas F, Suarez JI, Badenes R, Pelosi P, Robba C. THE MANTLE" bundle for minimizing cerebral hypoxia in severe traumatic brain injury. *Crit Care* 2023;27:13.
- Le Roux P, Menon DK, Citerio G, Vespa P, Bader MK, Brophy G, Diringner MN, Stocchetti N, Videtta W, Armonda R, et al. The International Multidisciplinary consensus conference on Multimodality monitoring in Neurocritical care: A list of recommendations and additional conclusions: A statement for Healthcare professionals from the Neurocritical care society and European society of intensive care medicine. *Neurocrit Care* 2014;21 Suppl 2:S282–96.
- Chesnut RM, Marshall LF, Klauber MR, Blunt BA, Baldwin N, Eisenberg HM, Jane JA, Marmarou A, Foulkes MA. The role of secondary brain injury in determining outcome from severe head injury. *J Trauma* 1993;34:216–22.
- Valadka AB, Gopinath SP, Contant CF, Uzura M, Robertson CS. Relationship of brain tissue P O 2 to outcome after severe head injury. *Crit Care Med* 1998;26:1576–81.
- Seo DE, Shin SD, Song KJ, Ro YS, Hong KJ, Park JH. Effect of hypoxia on mortality and disability in traumatic brain injury according to shock status: a cross-sectional analysis. *Am J Emerg Med* 2019;37:1709–15.
- Chang JJJ, Youn TS, Benson D, Mattick H, Andrade N, Harper CR, Moore CB, Madden CJ, Diaz-Arrastia RR. Physiologic and functional outcome correlates of brain tissue hypoxia in traumatic brain injury. *Crit Care Med* 2009;37:283–90.
- American College of Surgeons Trauma Quality Improvement Program. Best practices in the management of traumatic brain injury. January 2015. Available: [https://www.facs.org/media/mkej5u3b/tbi\\_guidelines.pdf](https://www.facs.org/media/mkej5u3b/tbi_guidelines.pdf) [Accessed 18 Feb 2024].
- Okonkwo DO, Shutter LA, Moore C, Temkin NR, Puccio AM, Madden CJ, Andaluz N, Chesnut RM, Bullock MR, Grant GA, et al. Brain oxygen optimization in severe traumatic brain injury phase-II: A phase II randomized trial. *Crit Care Med* 2017;45:1907–14.
- Zauner A, Daugherty WP, Bullock MR, Warner DS. Brain oxygenation and energy metabolism: part I—biological function and pathophysiology. *Neurosurgery* 2002;51:289–301;
- Svedung Wettervik T, Beqiri E, Hånell A, Bögli SY, Placek M, Guilfoyle MR, Helmy A, Lavinio A, O'Leary R, Hutchinson PJ, et al. Brain tissue oxygen monitoring in traumatic brain injury-part II: isolated and combined insults in relation to outcome. *Crit Care* 2023;27:370.
- Payen J-F, Launey Y, Chabanne R, Gay S, Francony G, Gergele L, Vega E, Montcriol A, Couret D, Cottenceau V, et al. Intracranial pressure monitoring with and without brain tissue oxygen pressure monitoring for severe traumatic brain injury in France (OXY-TC): an open-label, randomised controlled superiority trial. *Lancet Neurol* 2023;22:1005–14.
- Leach MR, Shutter LA. How much oxygen for the injured brain - can invasive Parenchymal catheters help? *Curr Opin Crit Care* 2021;27:95–102.
- Carney N, Totten AM, O'Reilly C, Ullman JS, Hawryluk GWJ, Bell MJ, Bratton SL, Chesnut R, Harris OA, Kisson N, et al. Guidelines for the management of severe traumatic brain injury. *Neurosurgery* 2017;80:6–15.
- Hawryluk GWJ, Aguilera S, Buki A, Bulger E, Citerio G, Cooper DJ, Arrastia RD, Diringner M, Figaji A, Gao G, et al. A management algorithm for patients with intracranial pressure monitoring the Seattle International severe traumatic brain injury consensus conference (SIBICC). *Intensive Care Med* 2019;45:1783–94.
- Macdonald RL. Chapter 46: pathophysiology of chronic Subdural hematomas. In: Winn HR, ed. *Youmans and Winn neurological surgery*. 17th edn. Elsevier, 2017: 353–9.
- Mandai S, Sakurai M, Matsumoto Y. Middle Meningeal artery Embolization for refractory chronic Subdural Hematoma. *J Neurosurg* 2000;93:686–8.
- Okuma Y, Hirotsune N, Sato Y, Tanabe T, Muraoka K, Nishino S. Midterm follow-up of patients with middle Meningeal artery Embolization in intractable chronic Subdural Hematoma. *World Neurosurg* 2019;126:e671–8.
- Kan P, Maragos GA, Srivatsan A, Srinivasan V, Johnson J, Burkhardt J-K, Robinson TM, Salem MM, Chen S, Riina HA, et al. Middle Meningeal artery Embolization for chronic Subdural Hematoma: a multi-center experience of 154 consecutive Embolizations. *Neurosurgery* 2021;88:268–77.
- Seok JH, Kim JH, Kwon TH, Byun J, Yoon WK. Middle Meningeal artery Embolization for chronic Subdural Hematoma in elderly patients at high risk of surgical treatment. *J Cerebrovasc Endovasc Neurosurg* 2023;25:28–35.
- Orscelik A, Senol YC, Bilgin C, Kobeissi H, Arul S, Cloft H, Lanzino G, Kallmes DF, Brinjikji W. Middle Meningeal artery Embolization without surgical evacuation for chronic Subdural Hematoma: a single-center experience of 209 cases. *Front Neurol* 2023;14:1222131.
- Ironsides N, Nguyen C, Do Q, Ugiliweneza B, Chen CJ, Sieg EP, James RF, Ding D. Middle Meningeal artery Embolization for chronic Subdural Hematoma: a systematic review and meta-analysis. *J Neurointerv Surg* 2021;13:951–7.
- Shotar E, Meyblum L, Premat K, Lenck S, Degos V, Grand T, Cortese J, Pouvelle A, Pouliquen G, Mouyal S, et al. Middle Meningeal artery Embolization reduces the post-operative recurrence rate of at-risk chronic Subdural Hematoma. *J Neurointerv Surg* 2020;12:1209–13.
- Ng S, Derraz I, Boetto J, Dargazanli C, Poulen G, Gascou G, Lefevre PH, Molinari N, Lonjon N, Costalat V. Middle Meningeal artery Embolization as an adjuvant treatment to surgery for symptomatic chronic Subdural Hematoma: a pilot study assessing Hematoma volume Resorption. *J Neurointerv Surg* 2020;12:695–9.
- Ban SP, Hwang G, Byoun HS, Kim T, Lee SU, Bang JS, Han JH, Kim CY, Kwon OK, Oh CW. Middle Meningeal artery Embolization for chronic Subdural Hematoma. *Radiology* 2018;286:992–9.
- Di Cristofori A, Remida P, Patassini M, Piergallini L, Buonanno R, Bruno R, Carrabba G, Pavesi G, Iaccarino C, Giussani CG. Middle Meningeal artery Embolization for chronic Subdural hematomas. A systematic review of the literature focused on indications, technical aspects, and future possible perspectives. *Surg Neurol Int* 2022;13:94.
- Nia AM, Srinivasan VM, Siddiq F, Thomas A, Burkhardt JK, Lall RR, Kan P. Trends and outcomes of primary, rescue, and adjunct middle Meningeal artery Embolization for chronic Subdural hematomas. *World Neurosurg* 2022;164:e568–73.
- Salem MM, Kuybu O, Nguyen Hoang A, Baig AA, Khorasanizadeh M, Baker C, Hunsaker JC, Mendez AA, Cortez G, Davies JM, et al. Middle Meningeal artery Embolization for chronic Subdural Hematoma: predictors of clinical and radiographic failure from 636 Embolizations. *Radiology* 2023;307:e222045.
- Siahaan AMP, Indharty S, Tandean S, Tommy T, Loe ML, Nainggolan BWM, Pangestu D, Susanto M. Middle Meningeal artery Embolization and pediatric chronic Subdural Hematoma: a systematic review of the literature. *Neurosurg Rev* 2023;46:239.
- Lulla A, Lumba-Brown A, Totten AM, Maher PJ, Badjatia N, Bell R, Donayri CTJ, Fallat ME, Hawryluk GWJ, Goldberg SA, et al. Prehospital guidelines for the management of traumatic brain injury. *Prehosp Emerg Care* 2023;27:507–38.
- Meyfroidt G, Bouzat P, Casar MP, Chesnut R, Hamada SR, Helbok R, Hutchinson P, Maas AIR, Manley G, Menon DK, et al. Management of moderate to severe traumatic brain injury: an update for the Intensivist. *Intensive Care Med* 2022;48:989–91.